



Salerno,  
31 ottobre 2014

**Formazione  
all'interpretazione del  
danno polmonare:  
IMAGING RX - TC - RM**

**S. BERTOLO**

**U.O. DI RADIOLOGIA  
DIAGNOSTICA  
ULSS 9**

*Direttore: G. Morana*

**I. BORZANI**

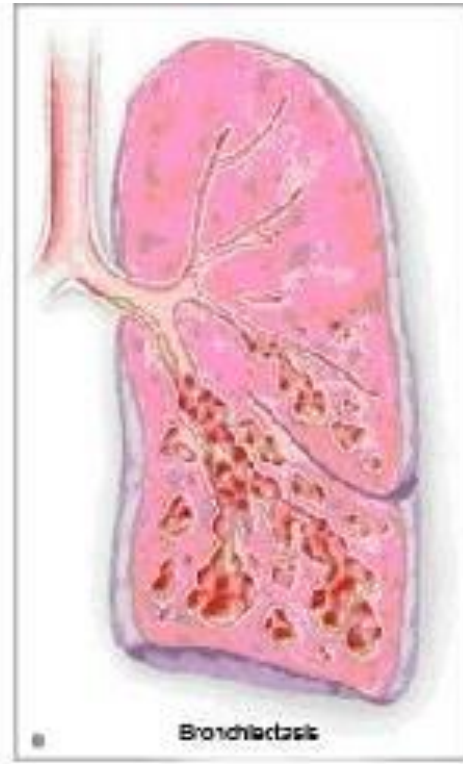
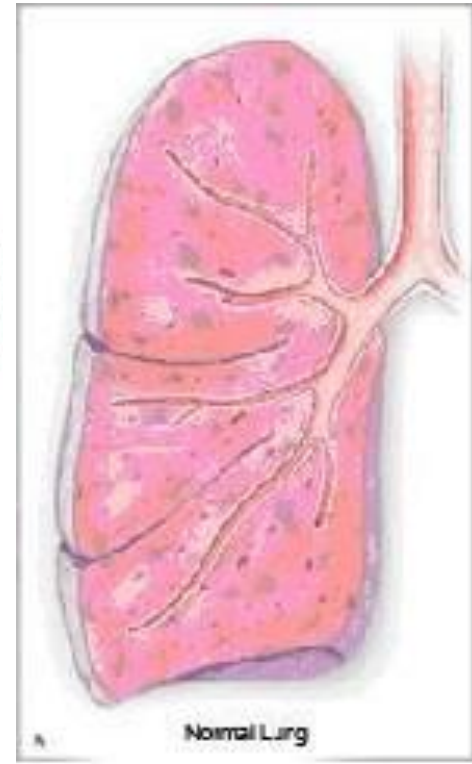
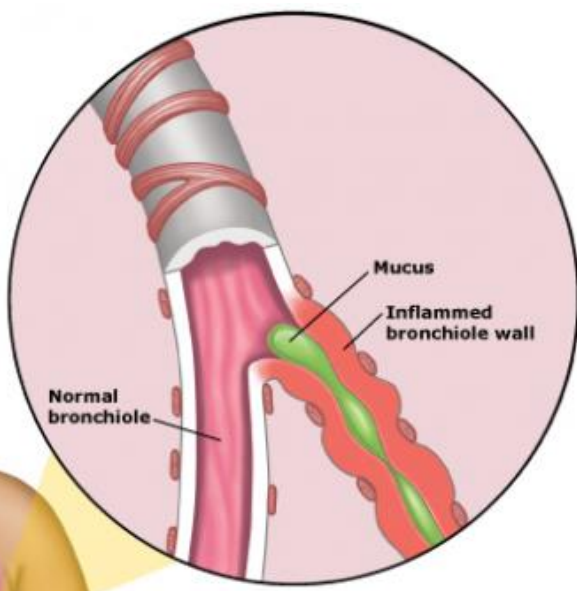
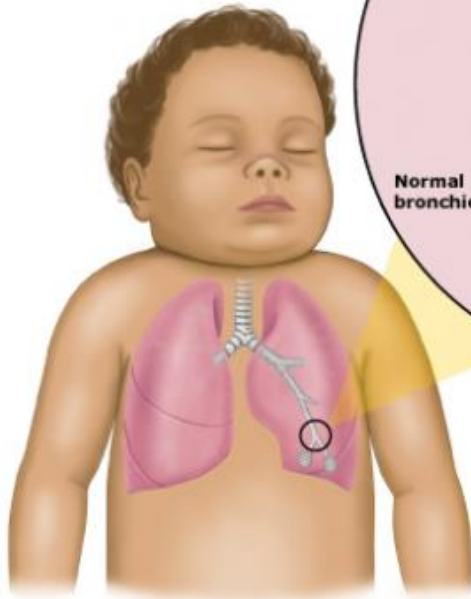
**U.O. DI RADIOLOGIA  
Fondazione IRCCS Ca'Granda-  
Ospedale Maggiore Policlinico**

*Direttore: P.R. Biondetti*

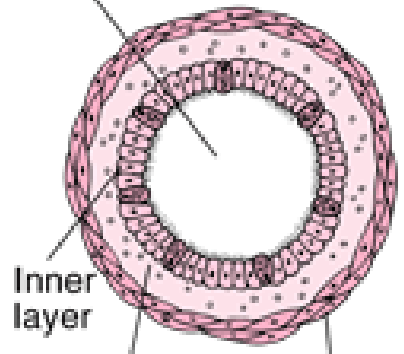


# Salute Polmonare

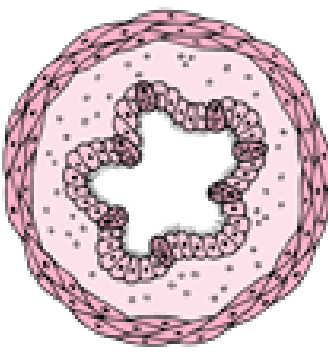
- La sfida nella cura della FC è preservare la normale morfologia delle vie aeree presente alla nascita
- Purtroppo non c'è modo di prevedere la severità o il pattern di interessamento polmonare
- Due importanti concetti di cura sono
  - Monitoraggio
  - Intervento precoce



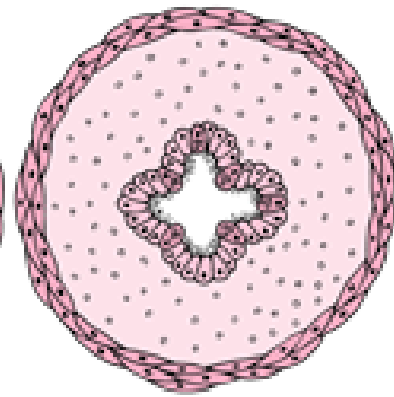
Air passageway



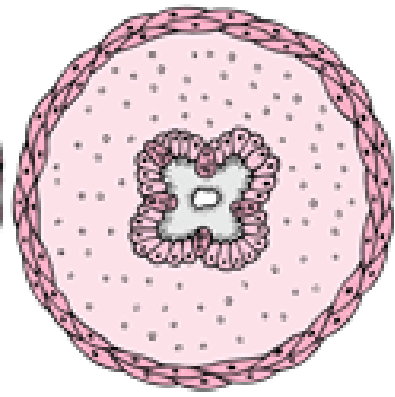
Normal Airway



Airway Spasm



Swollen Middle Layer




Mucus Plugs

# IMAGING in FC

## RX TORACE



## TC



## RM



# RX TORACE



# RX-TC TORACE



CONTRO

PRO

# RX torace: PRO-CONTRO



< radiazioni

rapida esecuzione

accessibilità



< informazioni

piccole alterazioni

interpretazione

# TC torace





# TC torace: PRO-CONTRO

> informazioni

rapida esecuzione

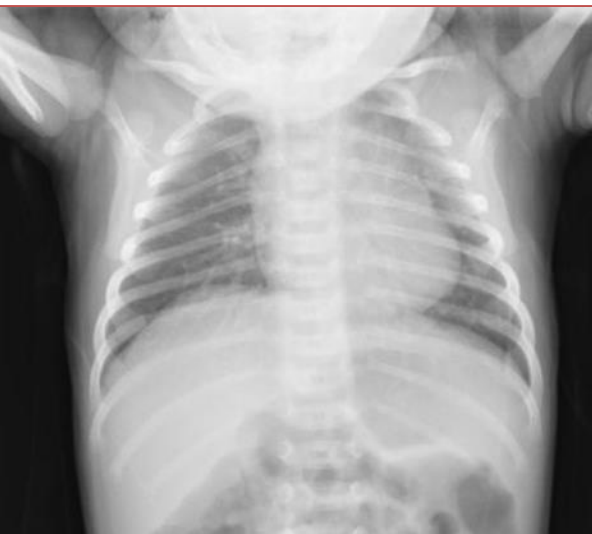> radiazioni

Studio  
statico/morfolo  
gico

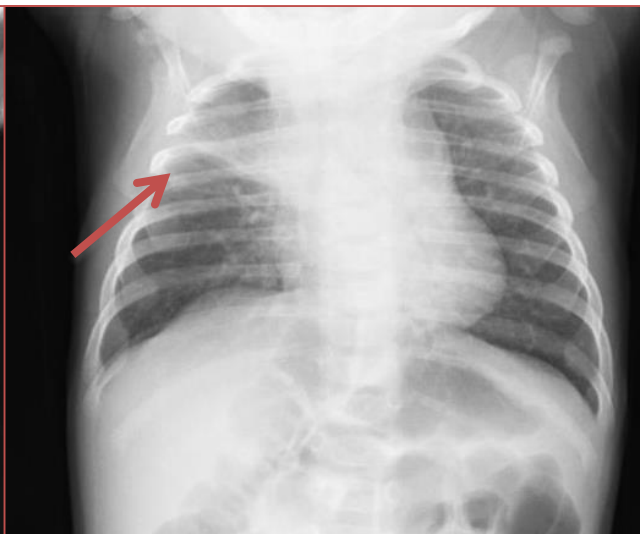
# RX TORACE-TC

## alterazioni radiologiche

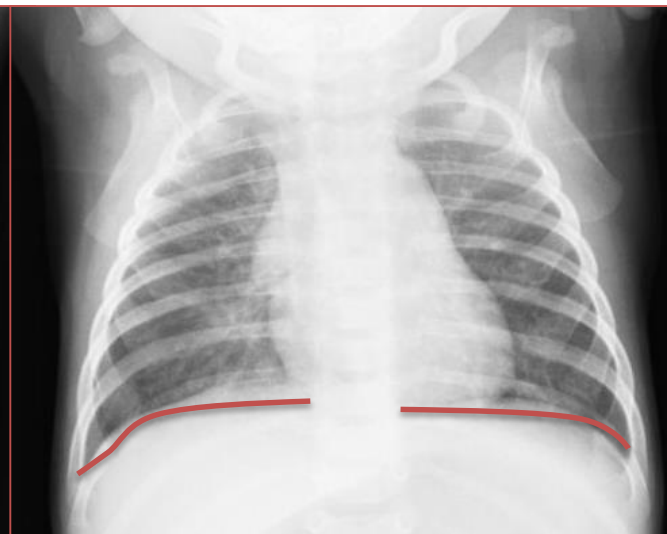
- IPERESPANSIONE aumento bilaterale del contenuto aereo
- BRONCHIECTASIE dilatazioni bronchiali
- ISPESSIMENTO PERIBRONCHIALE
- STASI MUCOSA ENDOBRONCHIALE
- ATELETTASIA – ADDENSAMENTI
- MICRONODULI/TREE-IN-BUD
- BOLLE
- ... ..



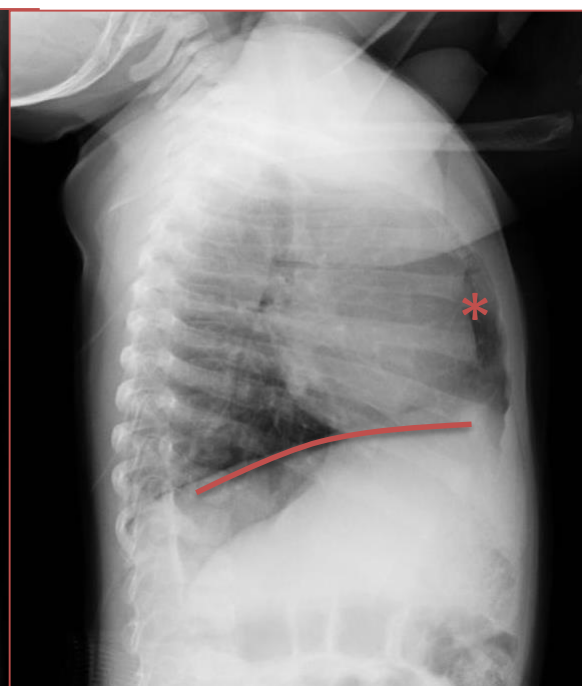
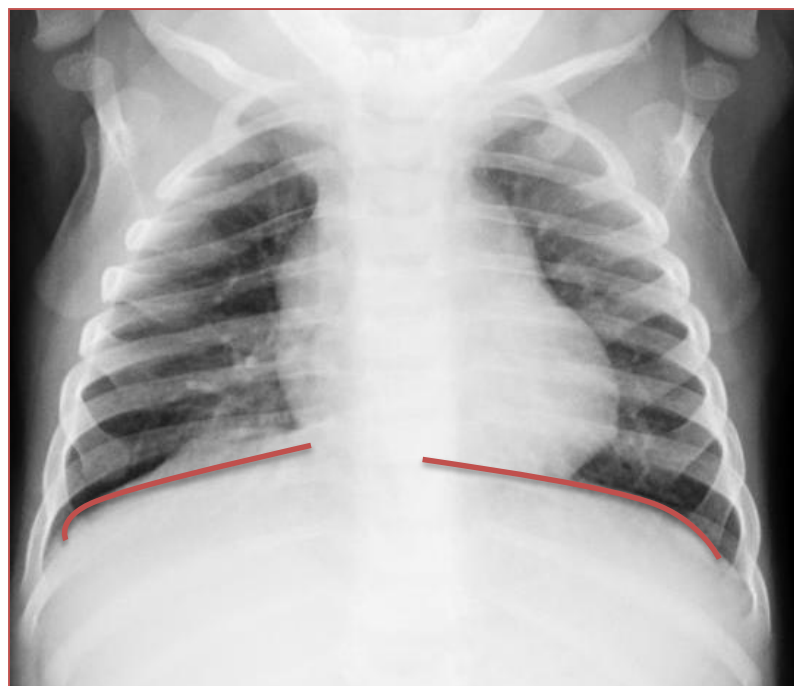20 days



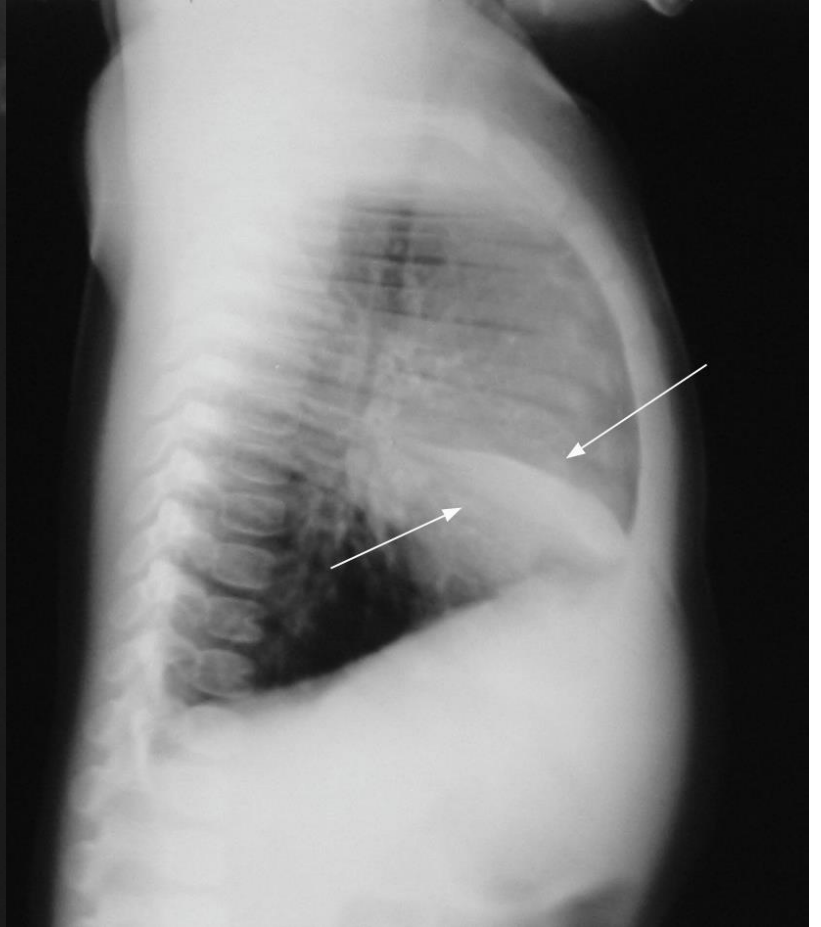
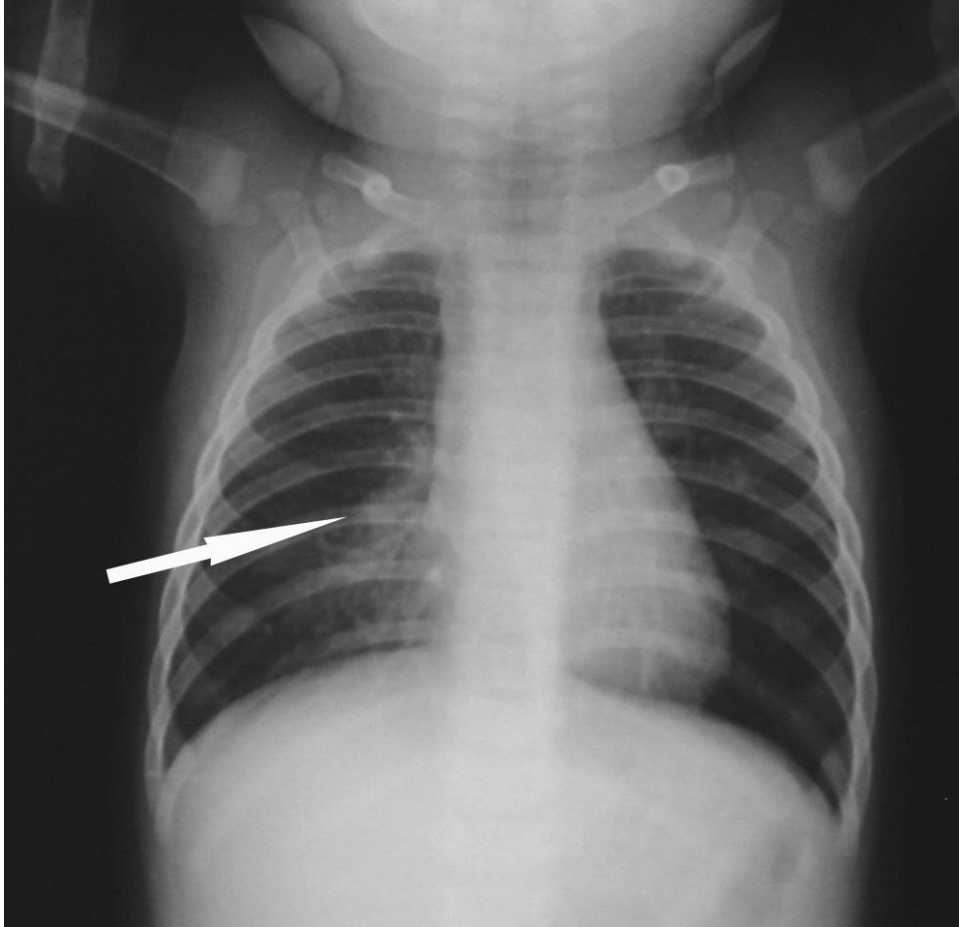
2 months



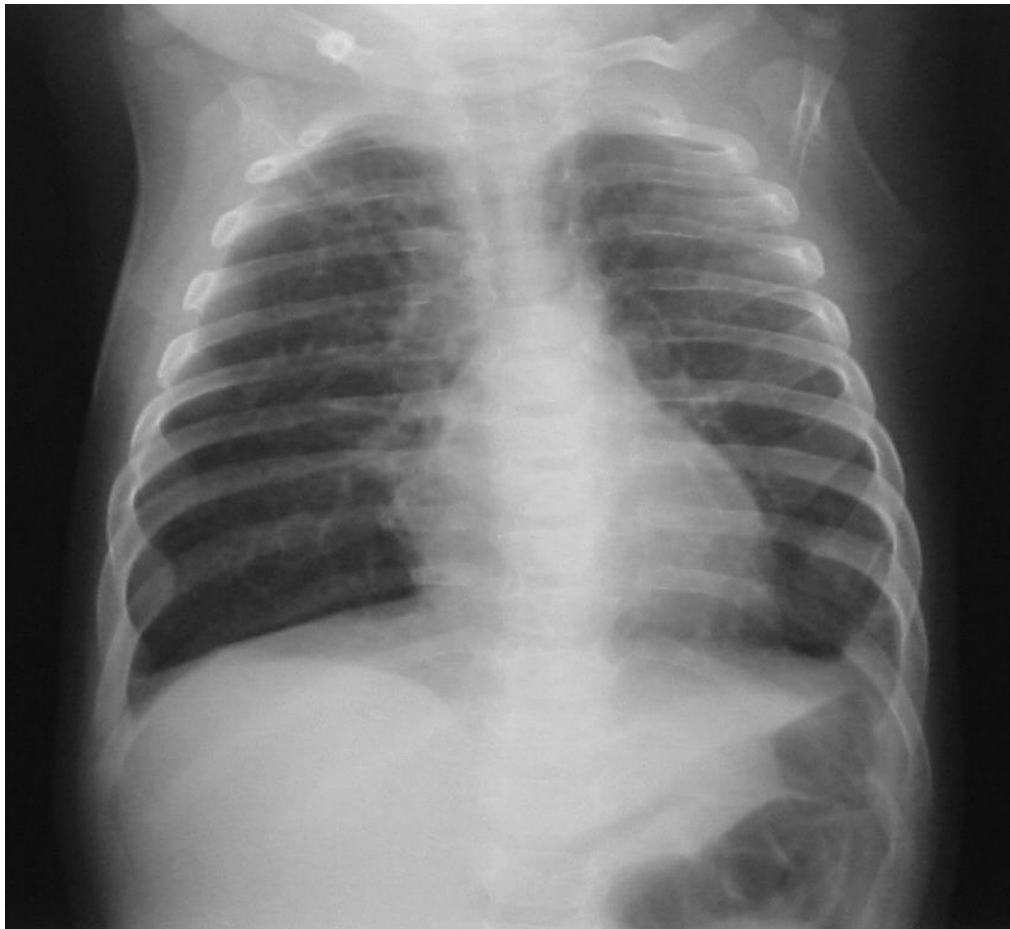3 months



8 months

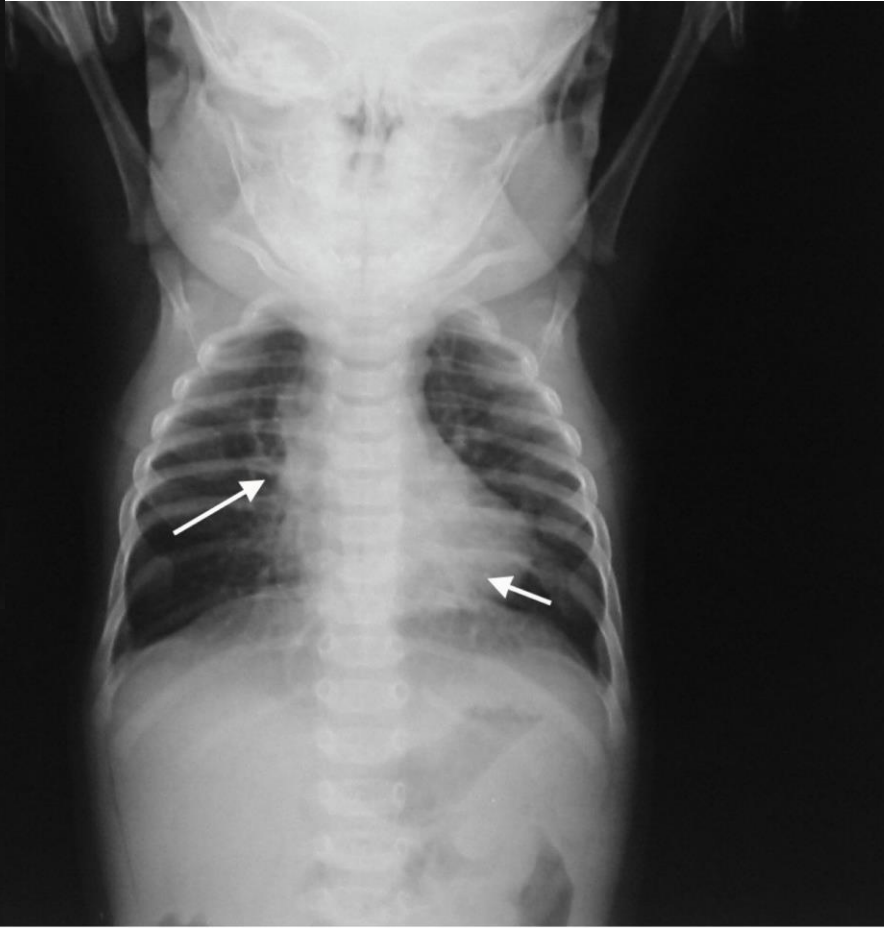

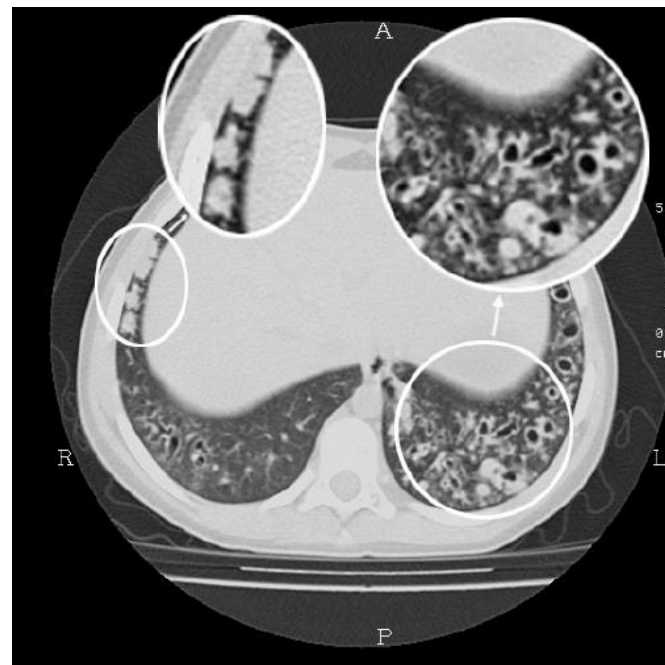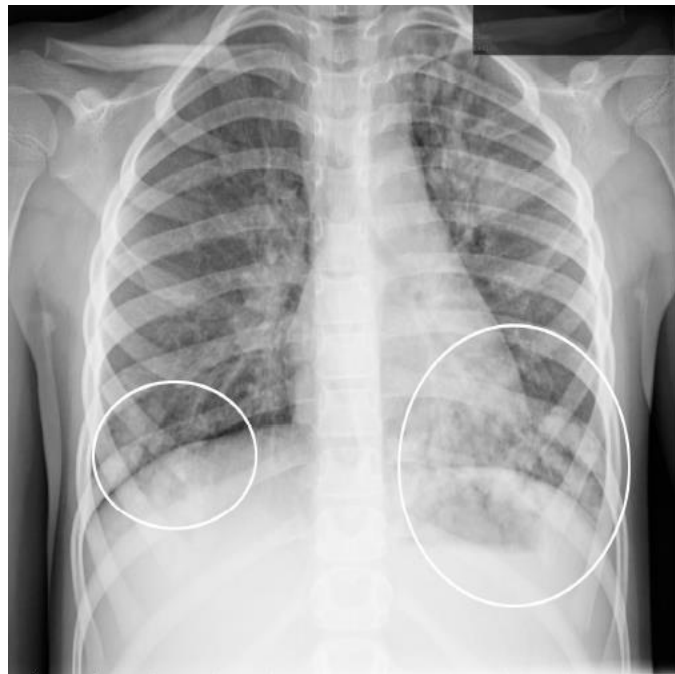
6 months



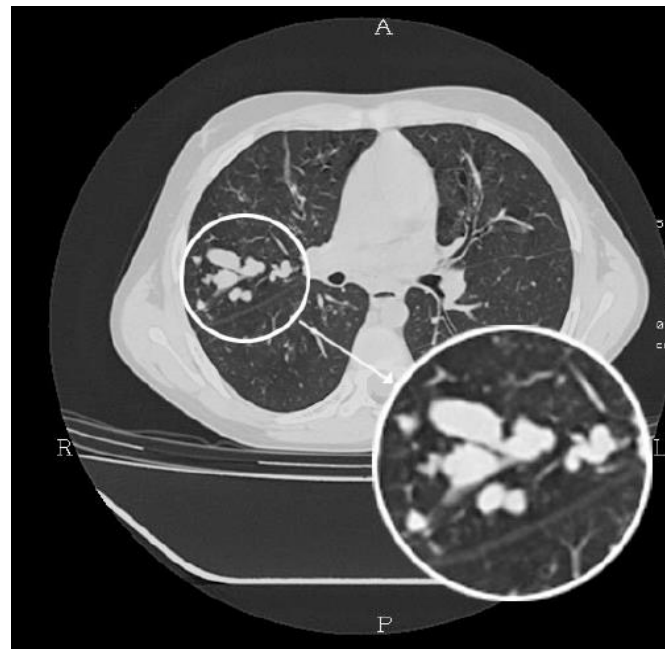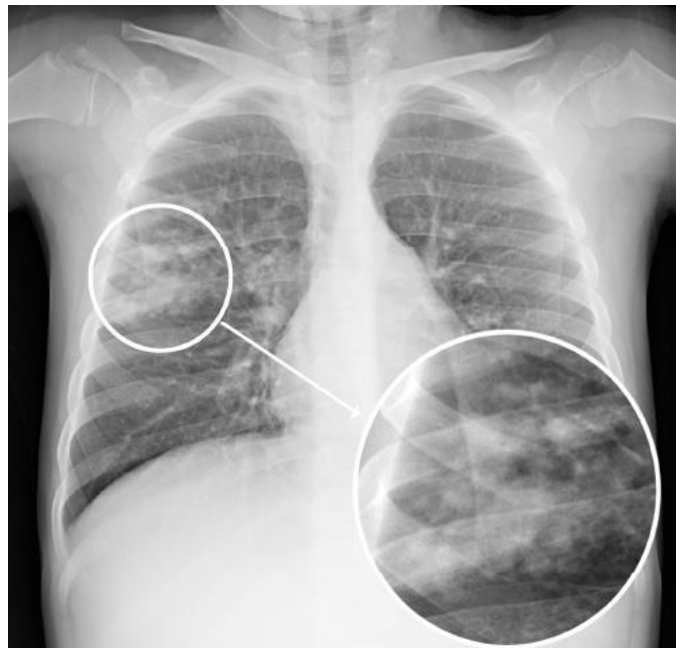3 months

4 months

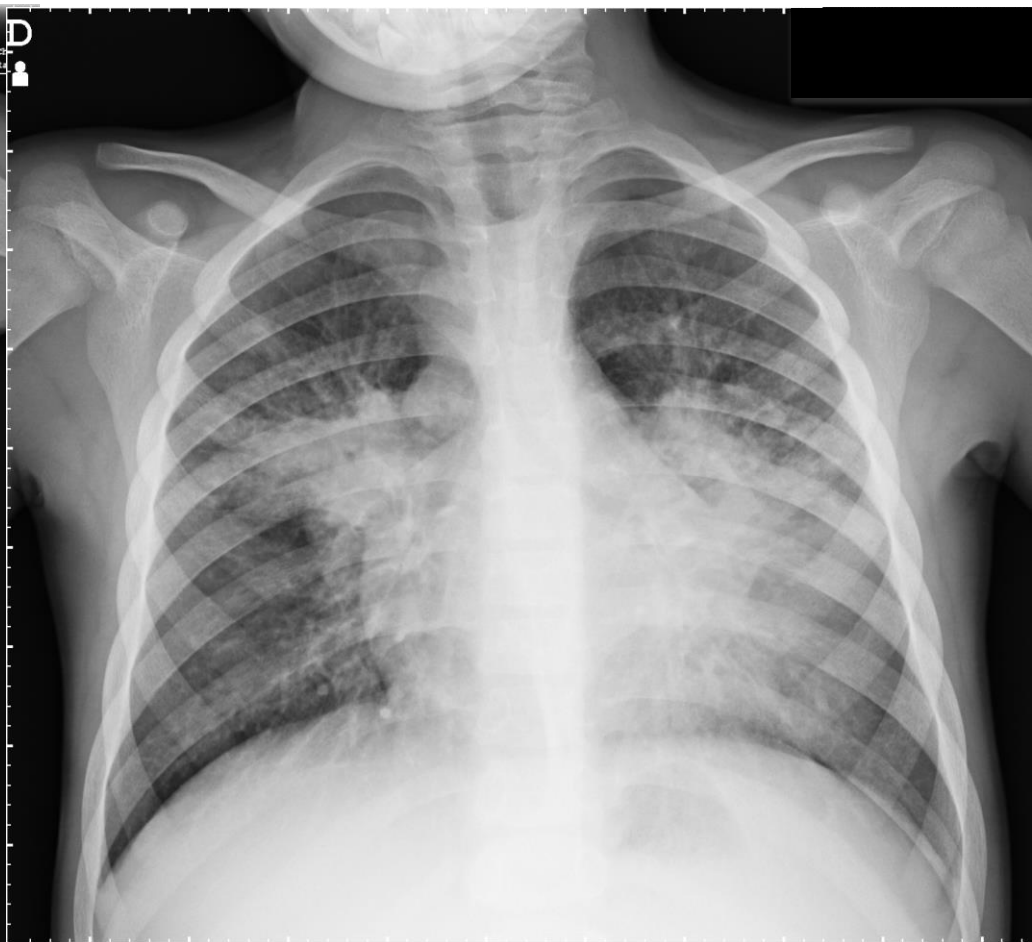
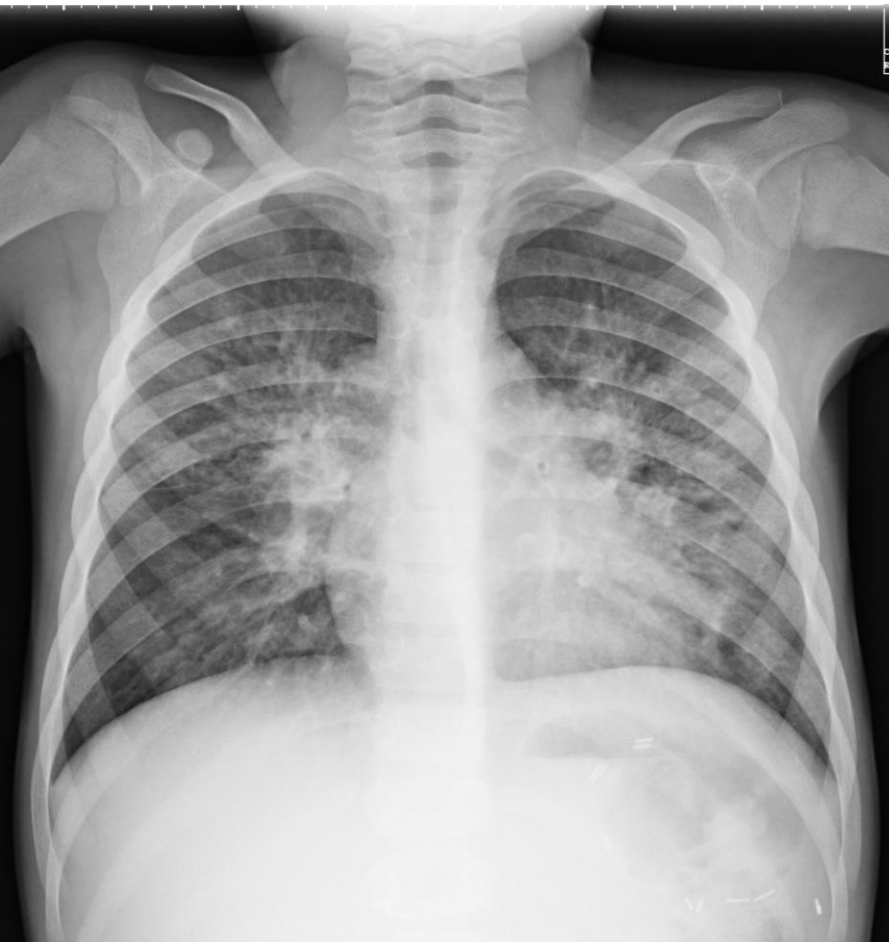


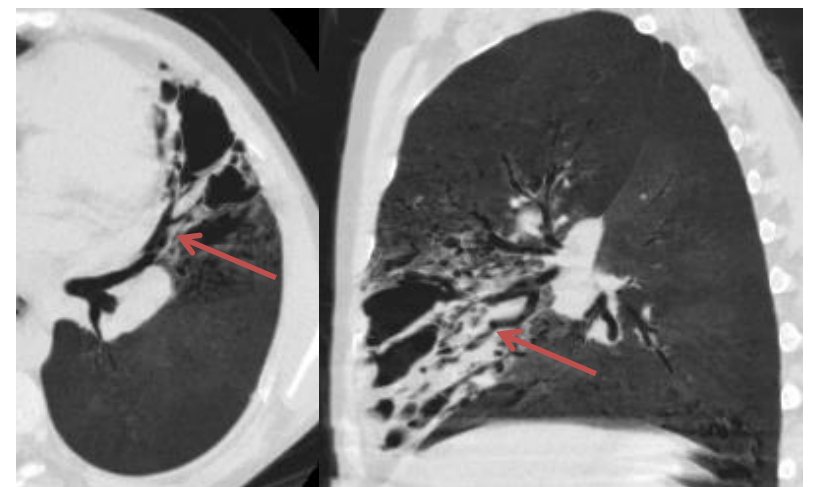
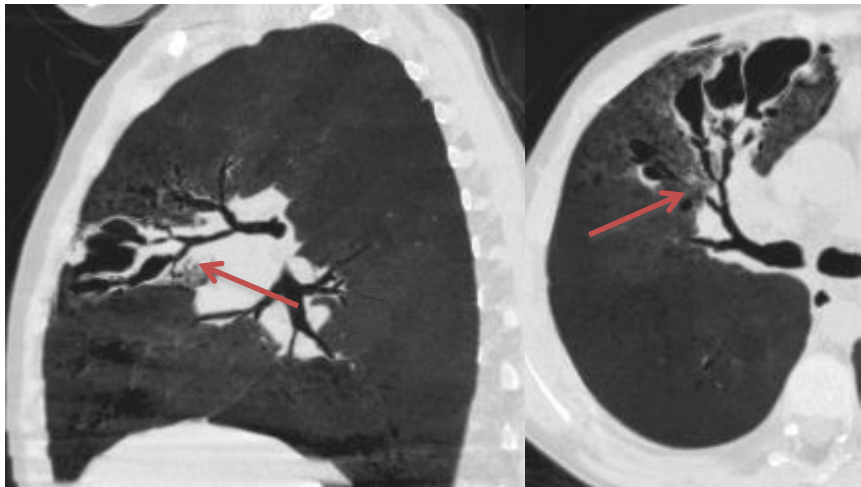
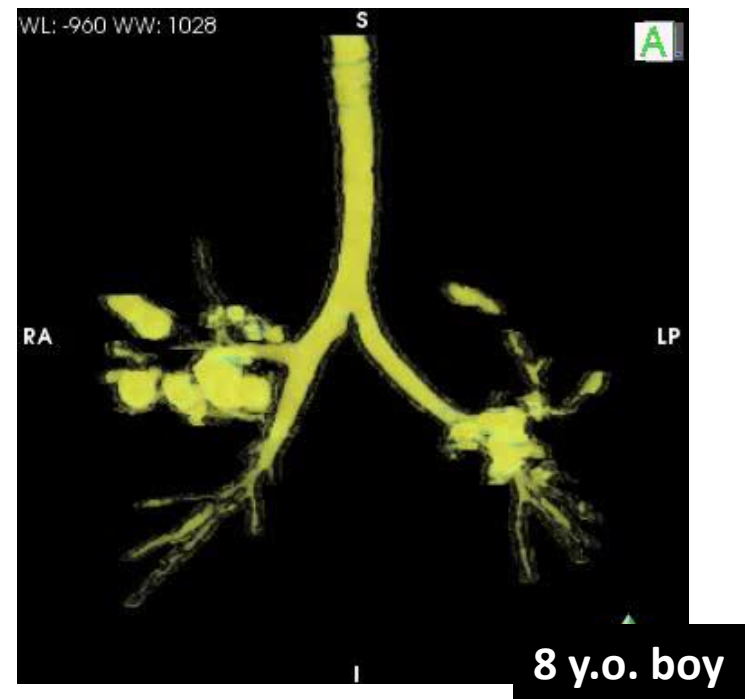
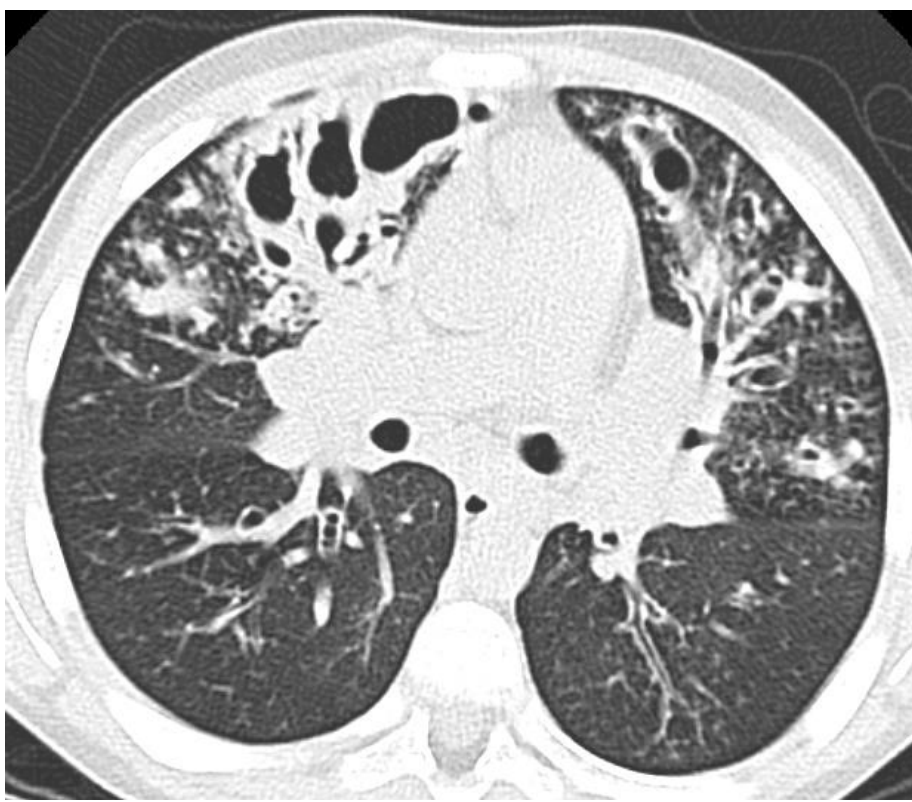
**8 years**



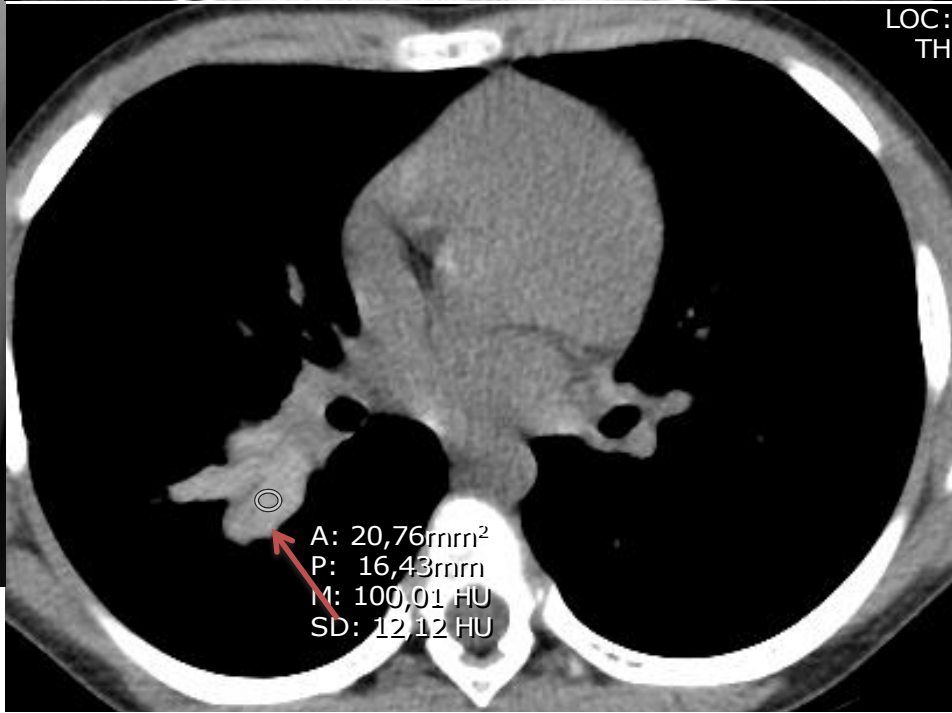
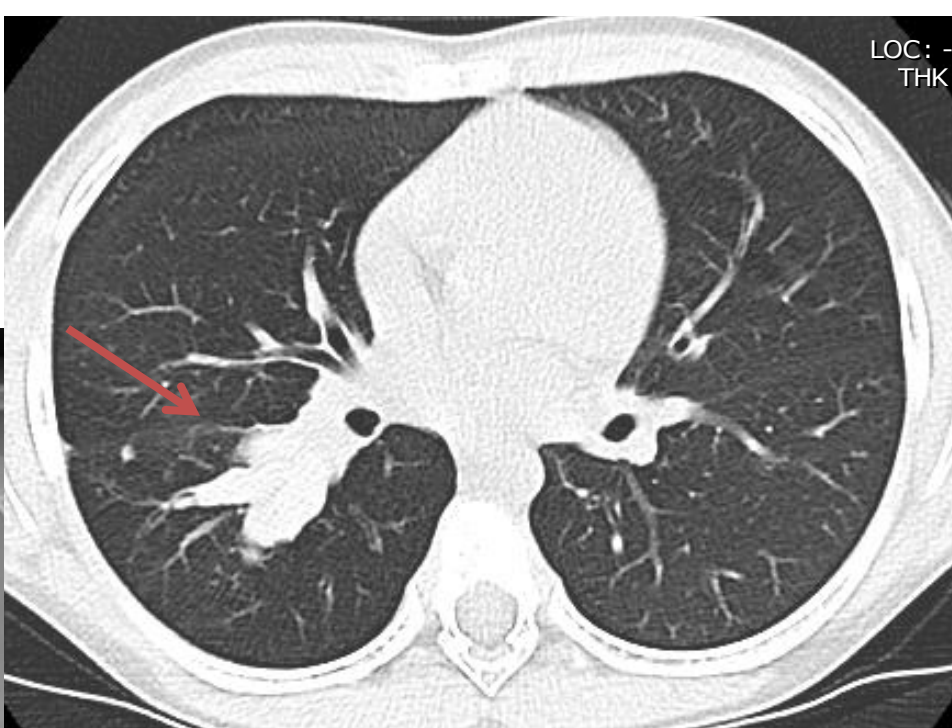
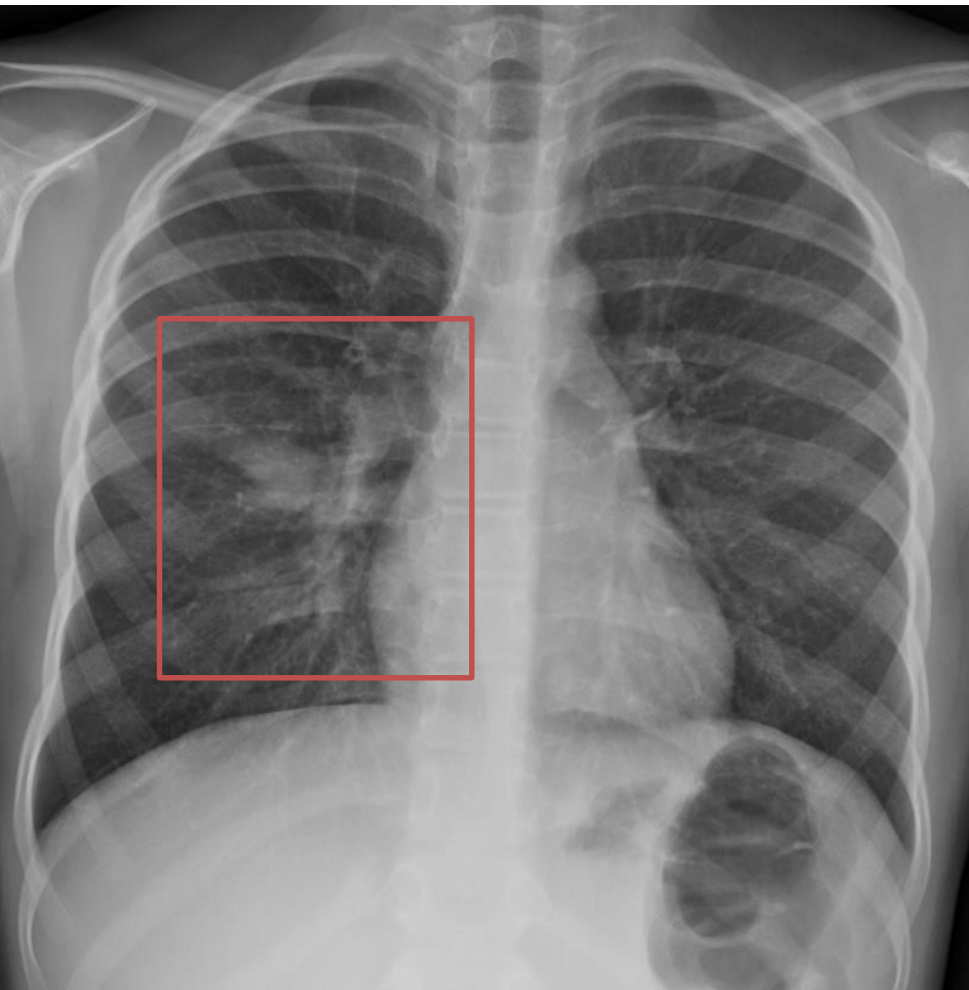
**8 years**

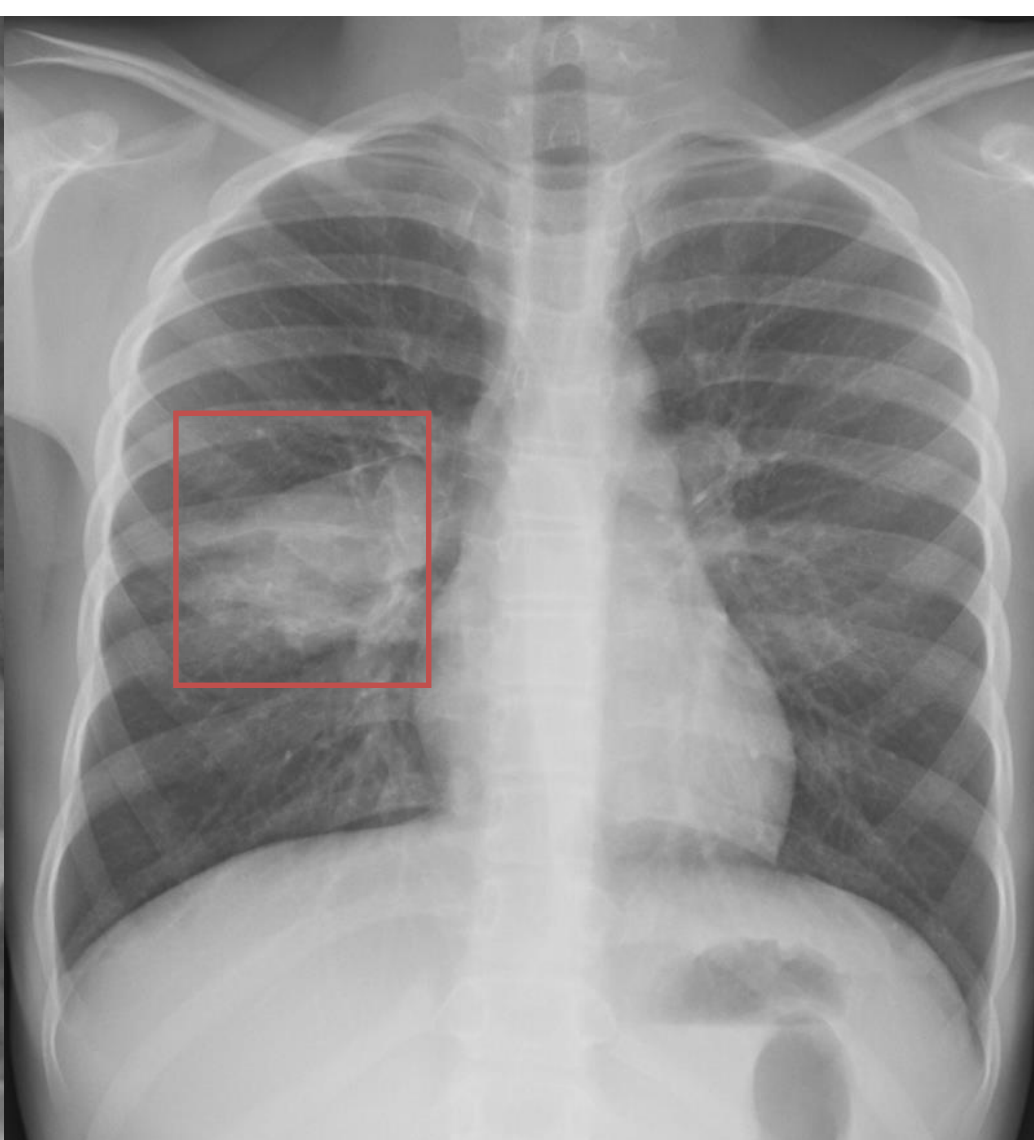
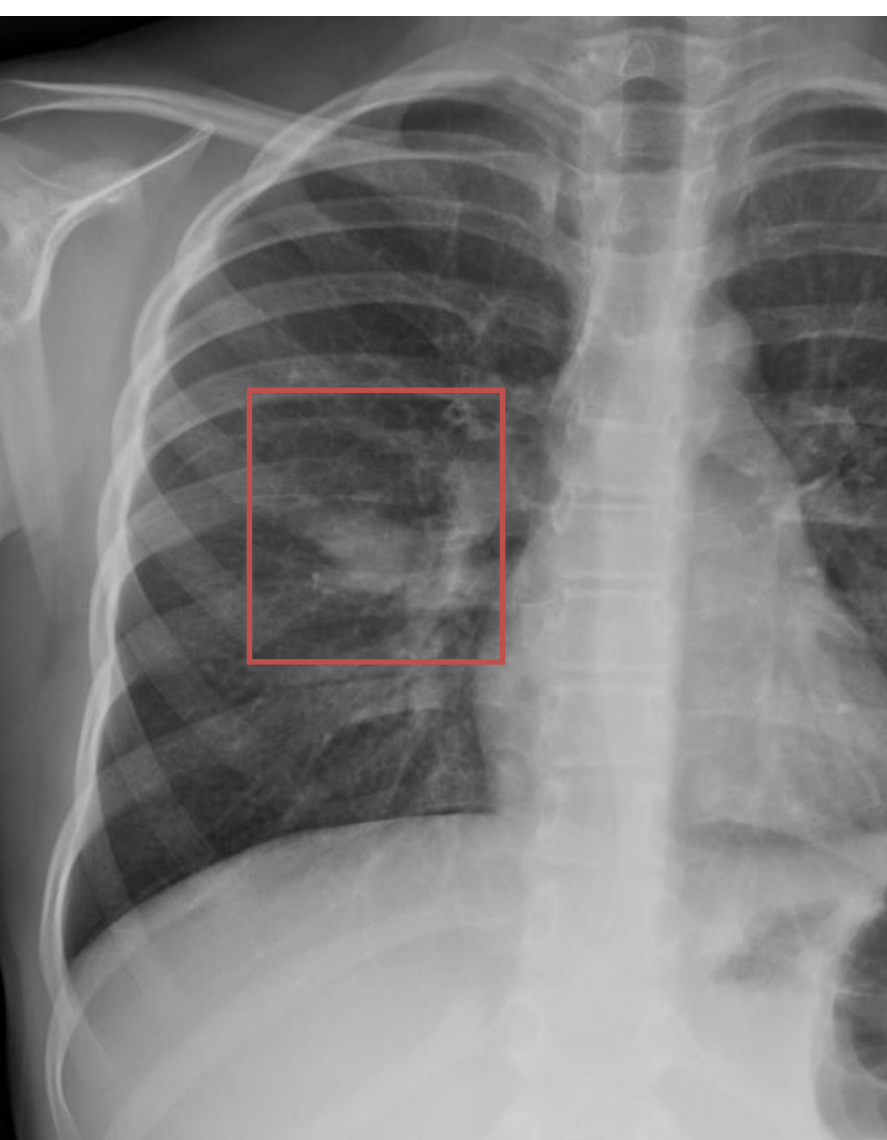


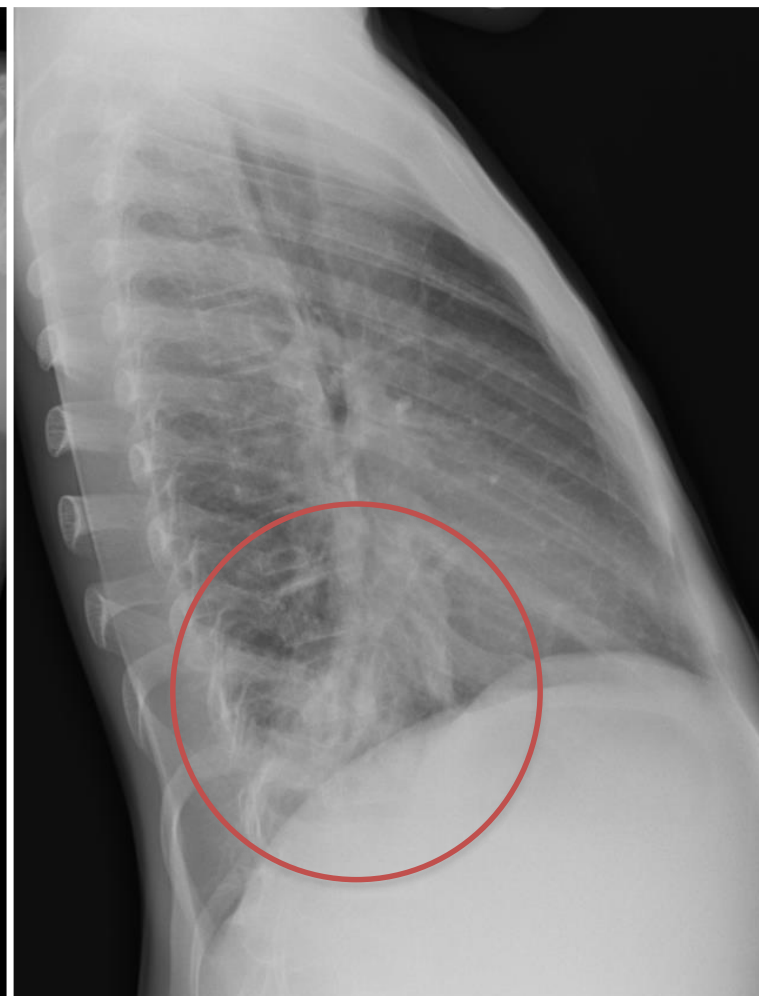
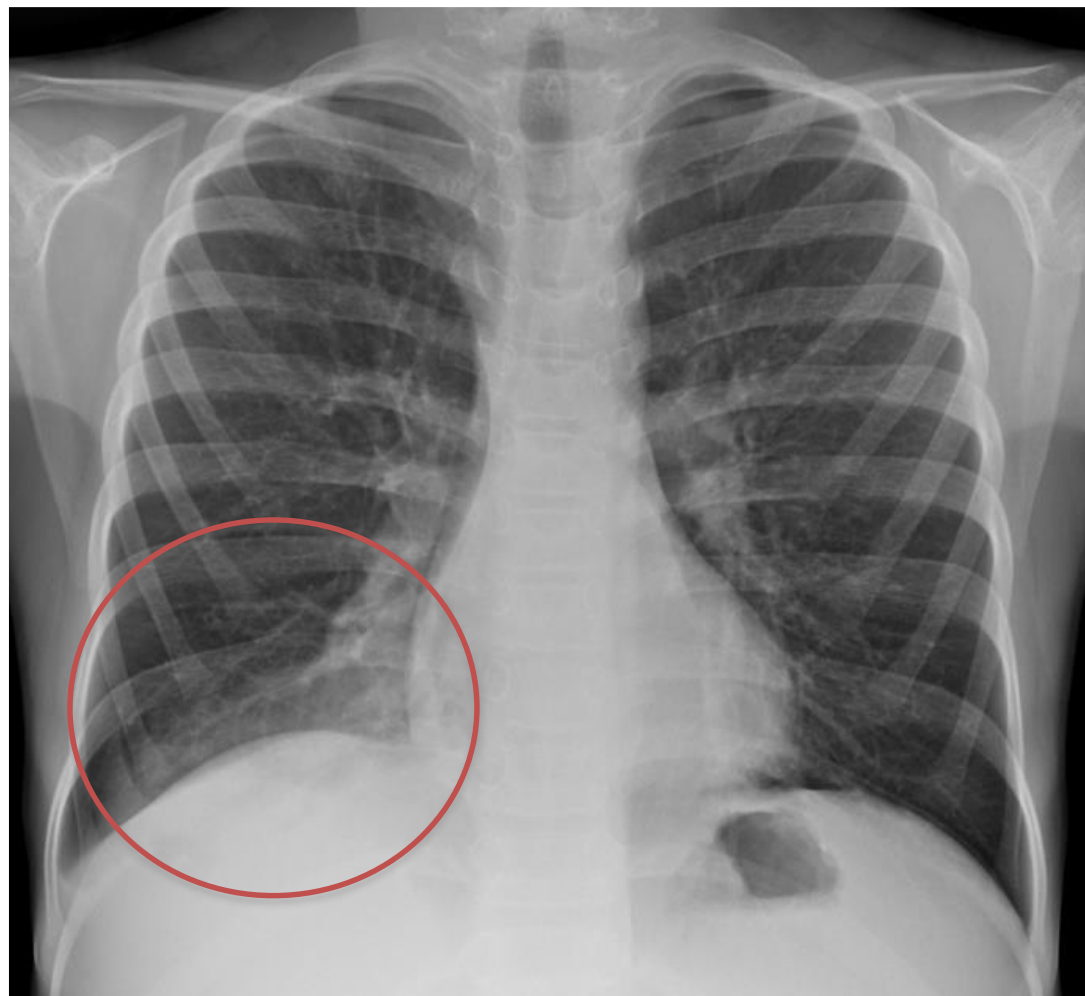
8 y. o. boy

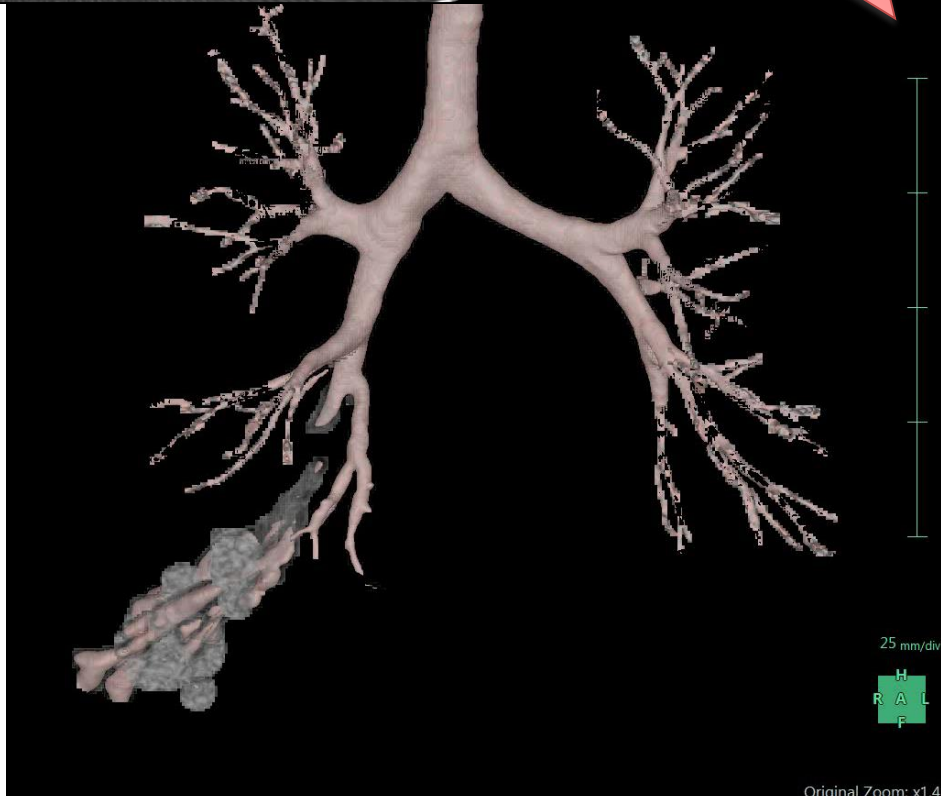
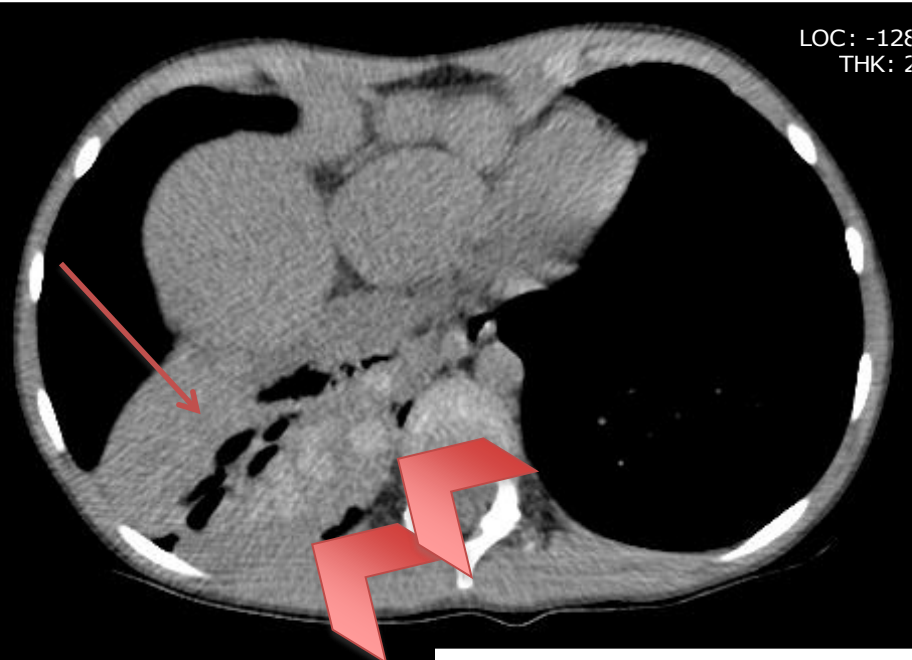
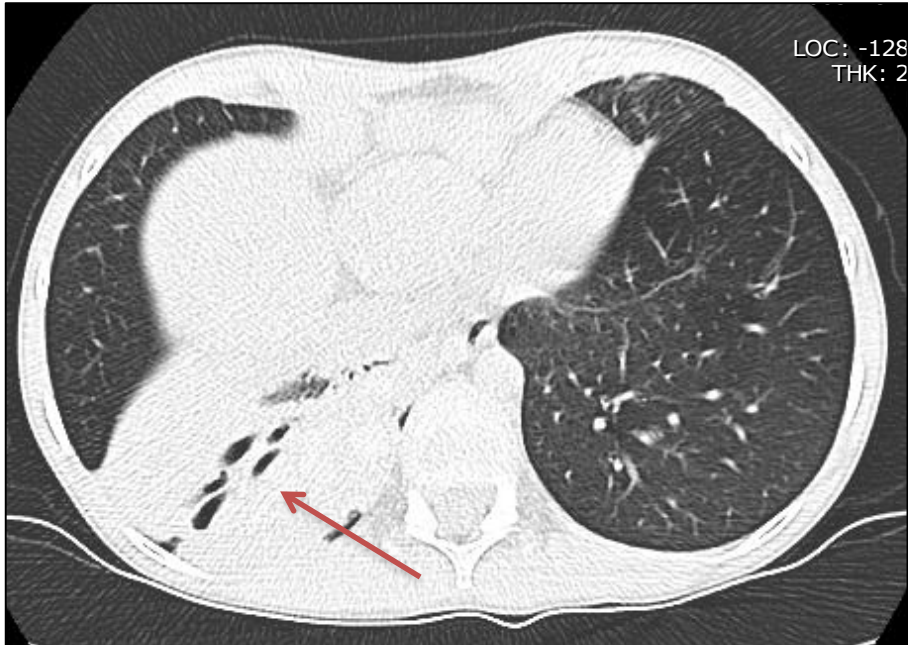





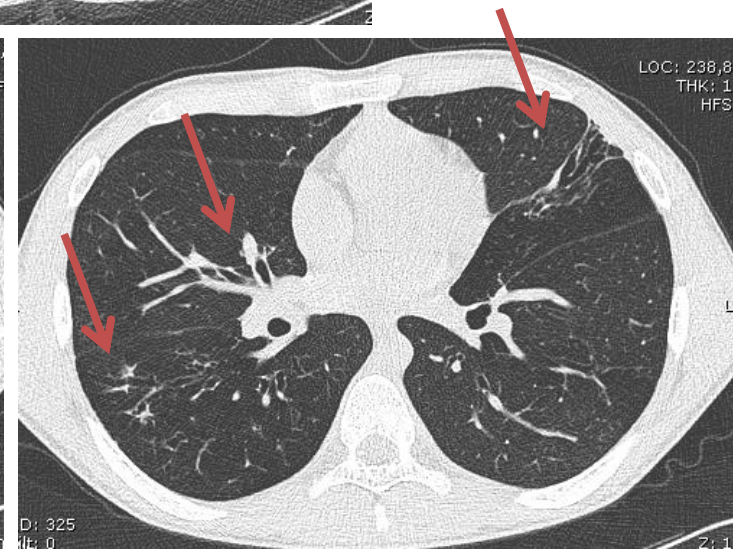
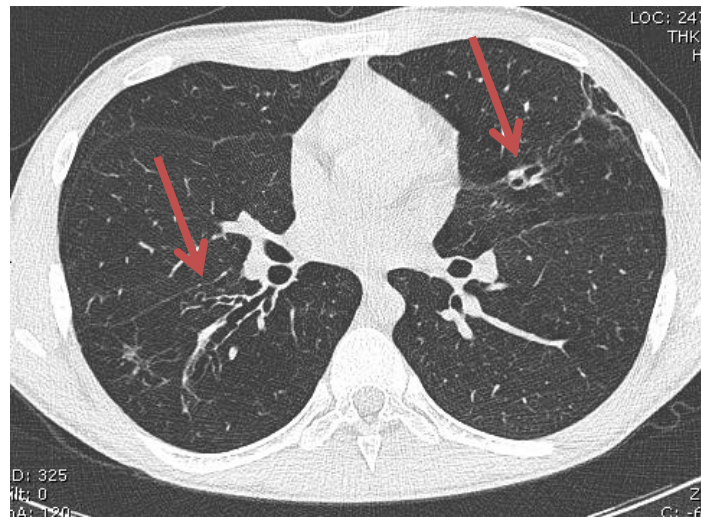
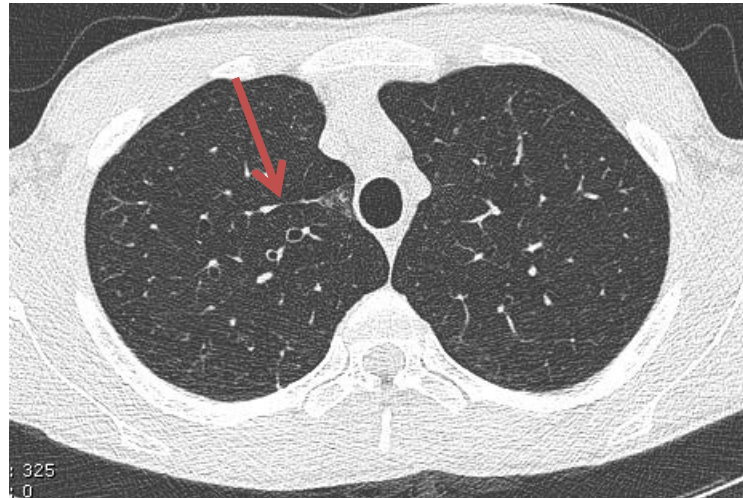
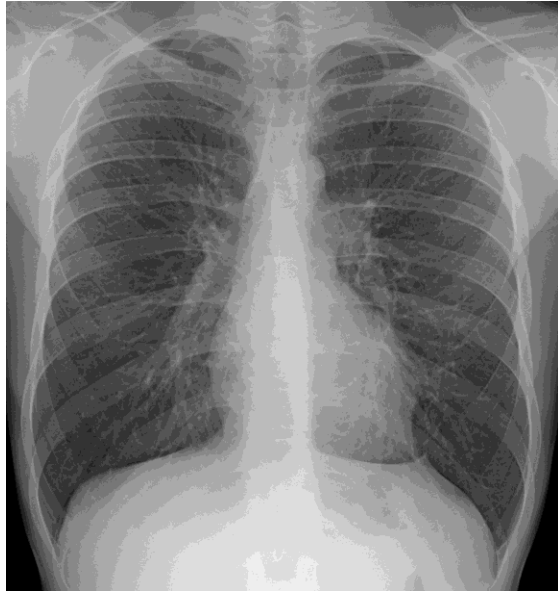




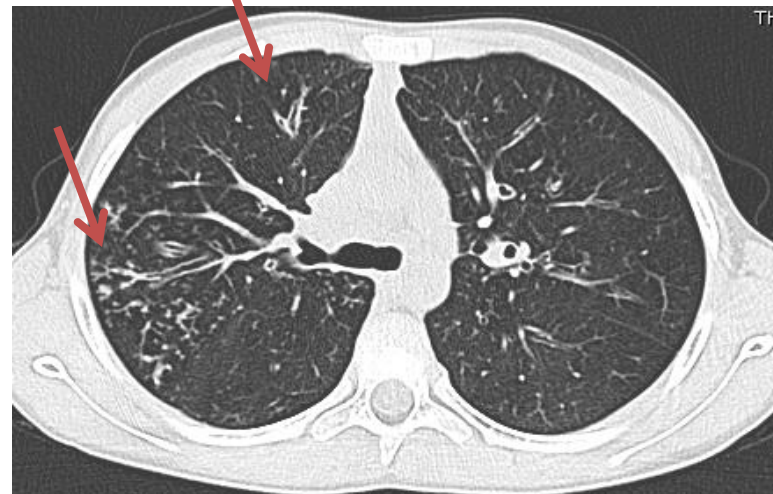
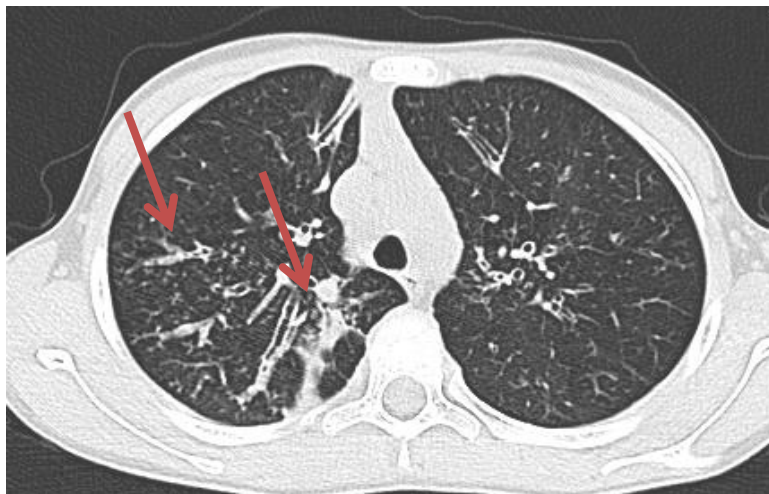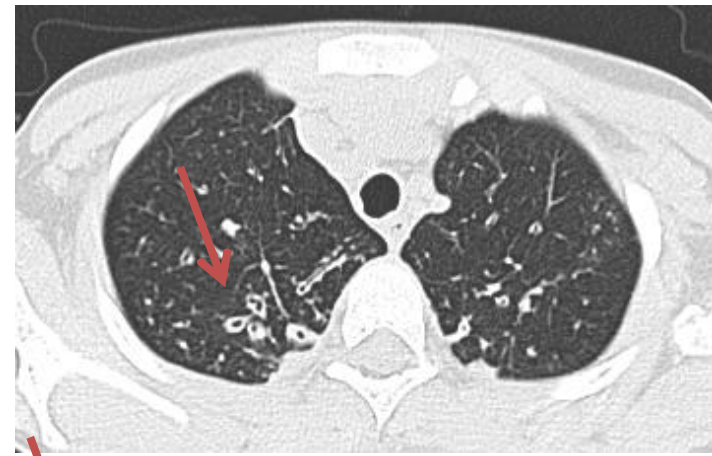


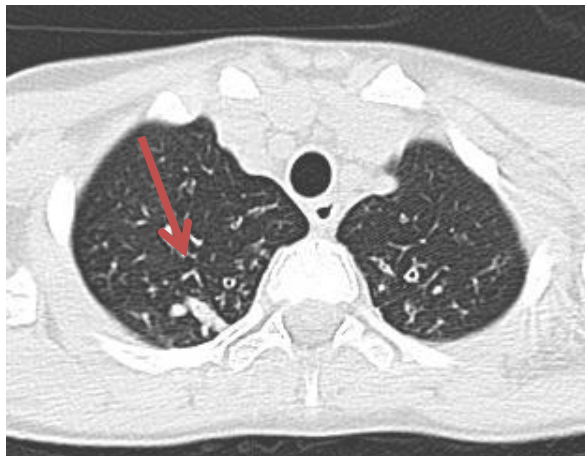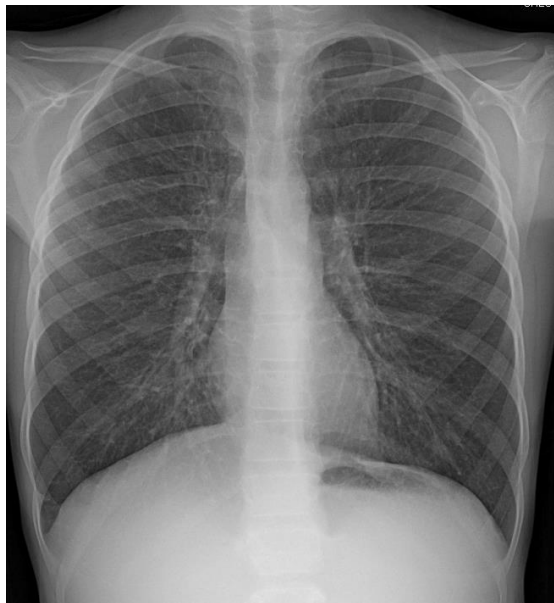# IMAGING RX-TC

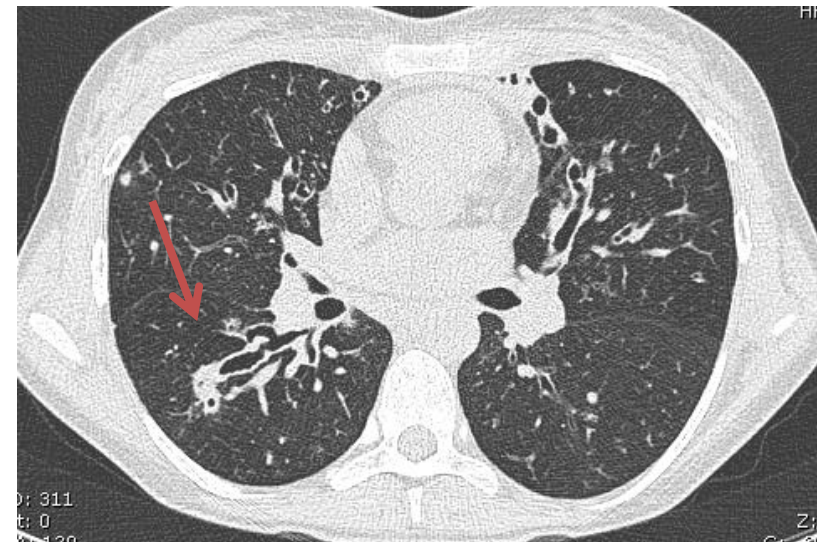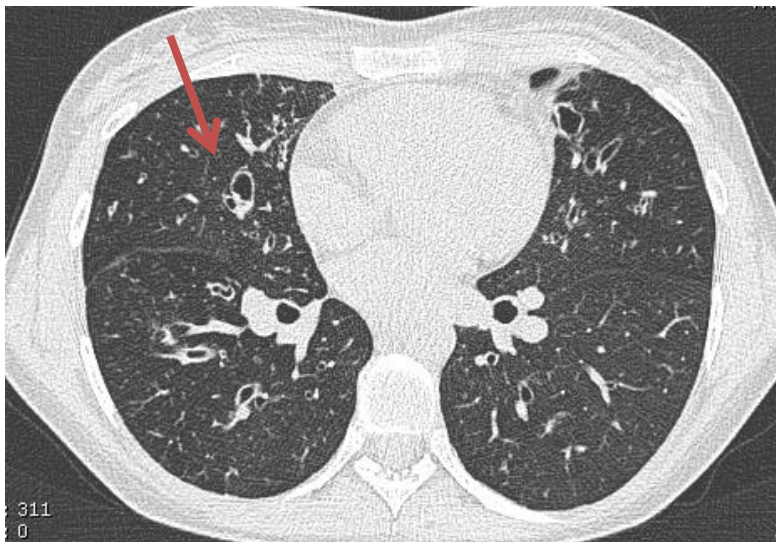
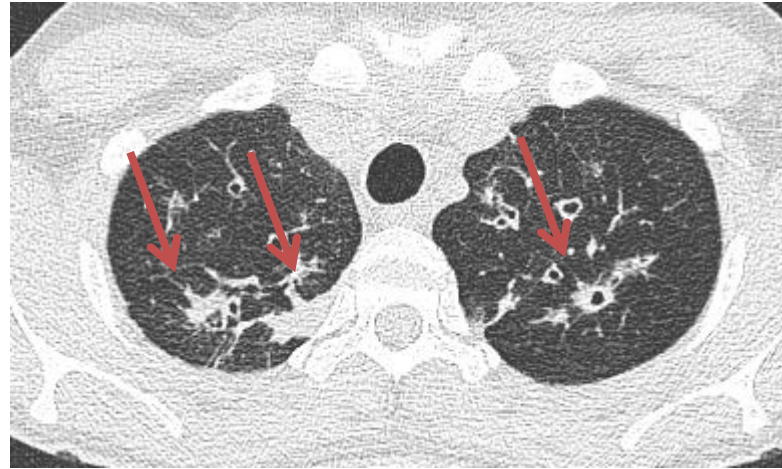
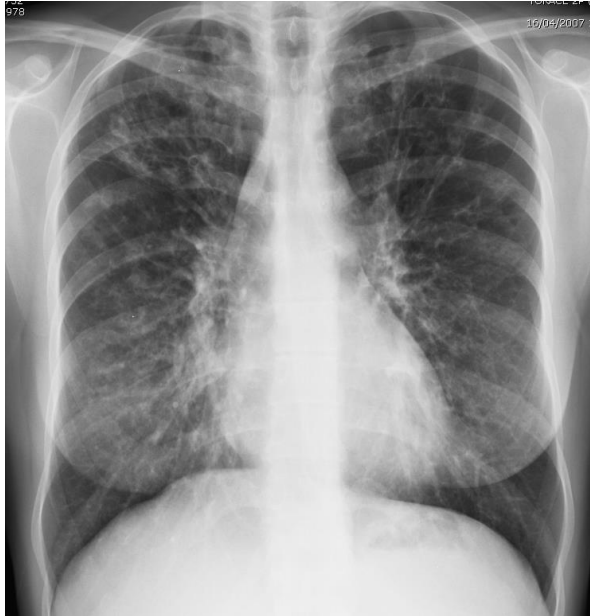Ispessimento delle pareti bronchiali



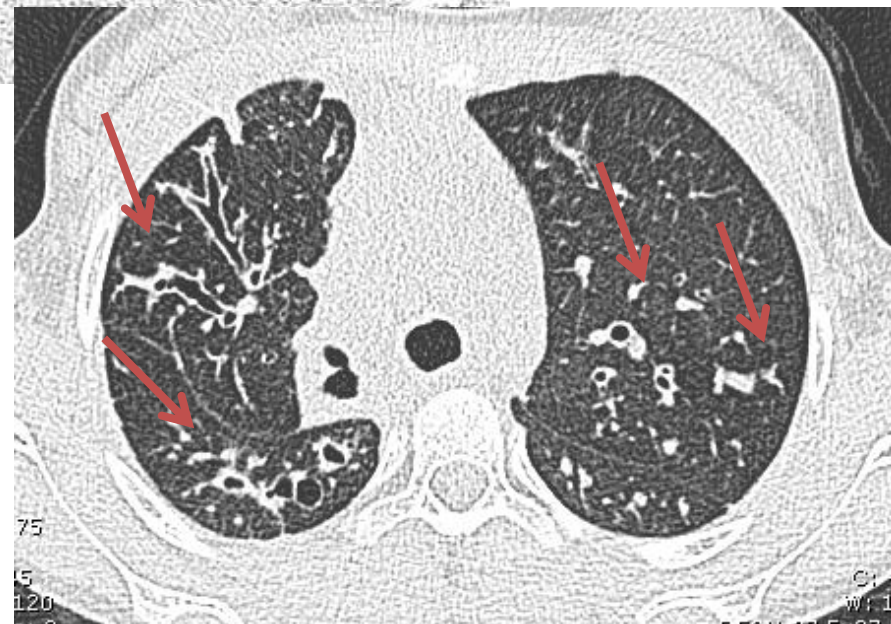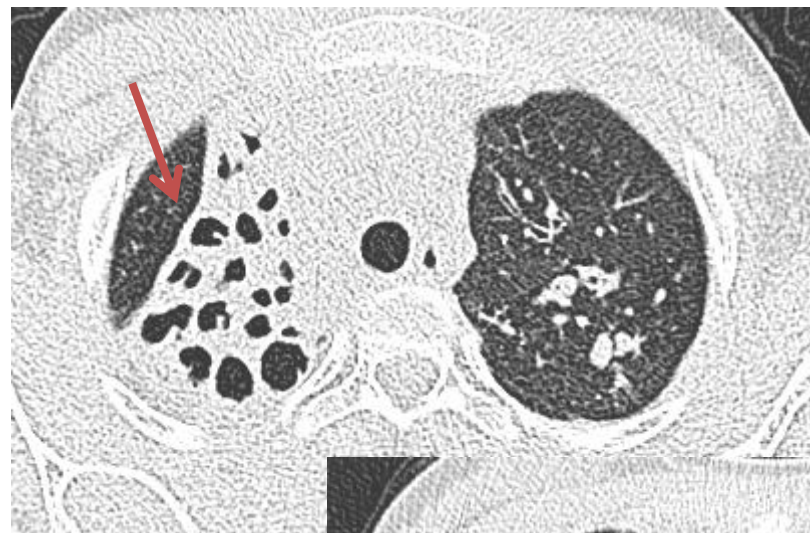
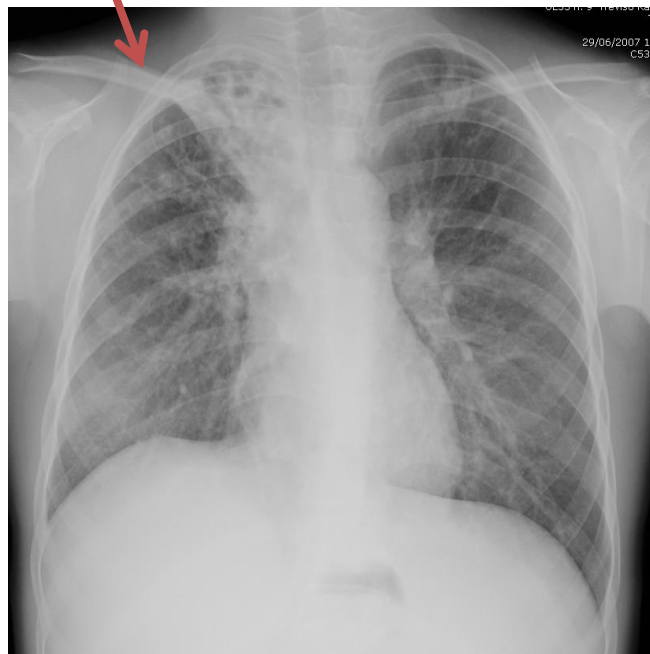
# Ispessimento delle pareti bronchiali, bronchiectasie, bronchiolectasie



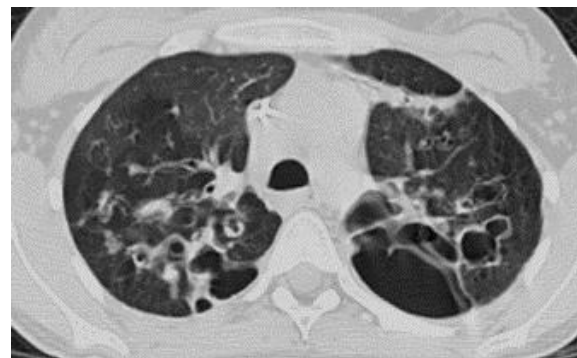
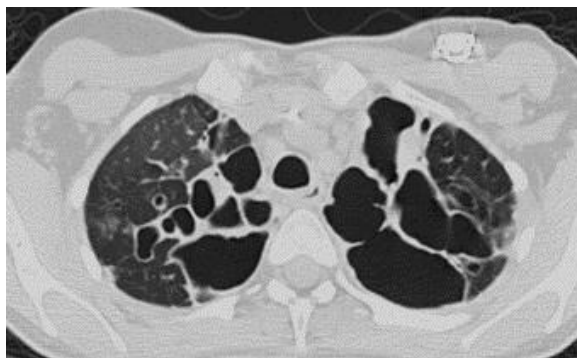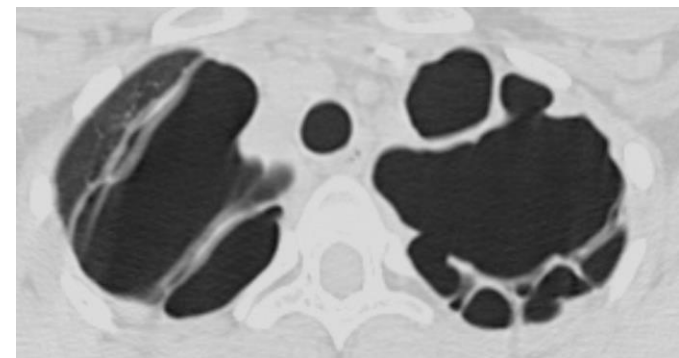
- Iperinsufflazione,
- ispessimento delle pareti bronchiali
- bronchiectasie
- mucus plugging



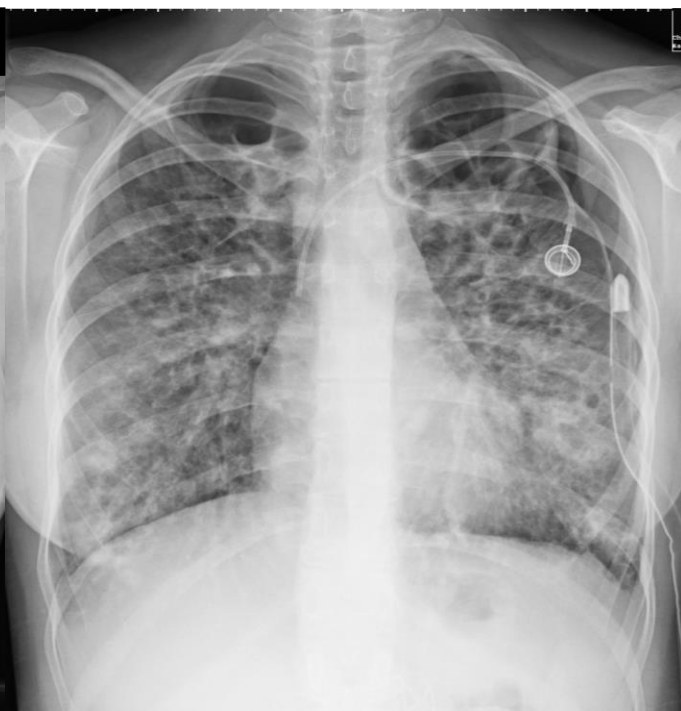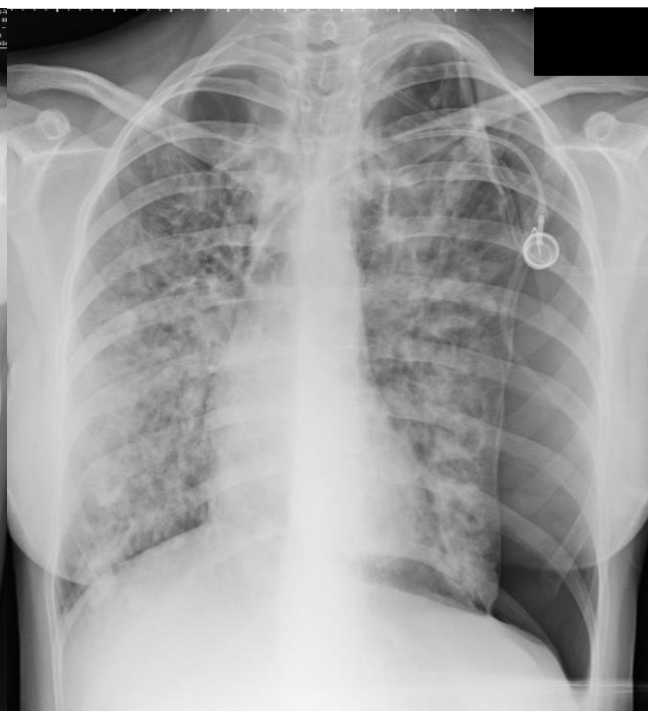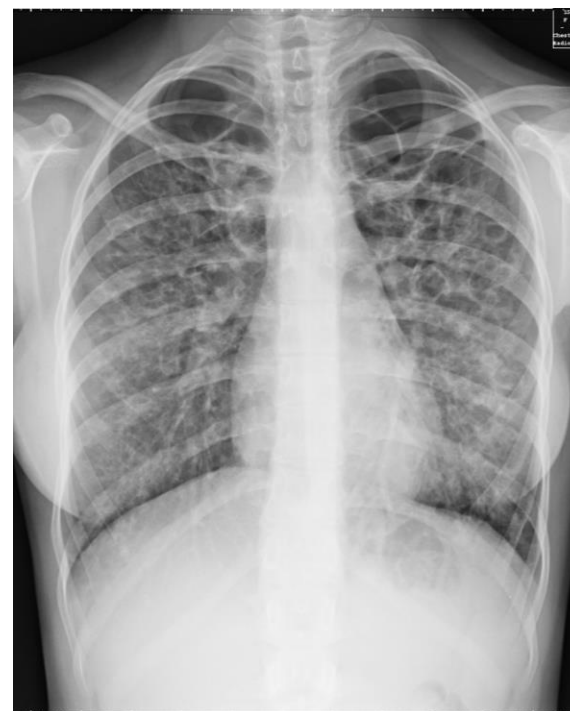- iperinsufflazione,
- ispessimento delle pareti bronchiali,
- bronchiectasie (>lobi superiori),
- mucus plugging,
- aree di consolidazione

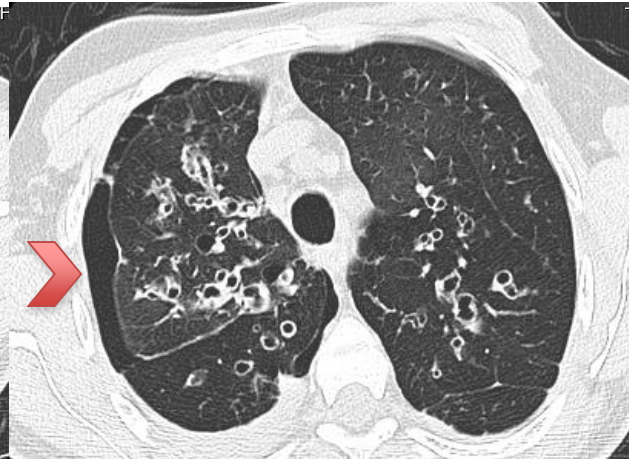
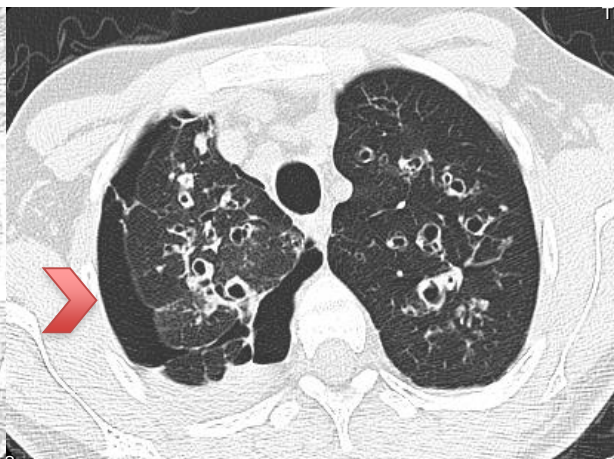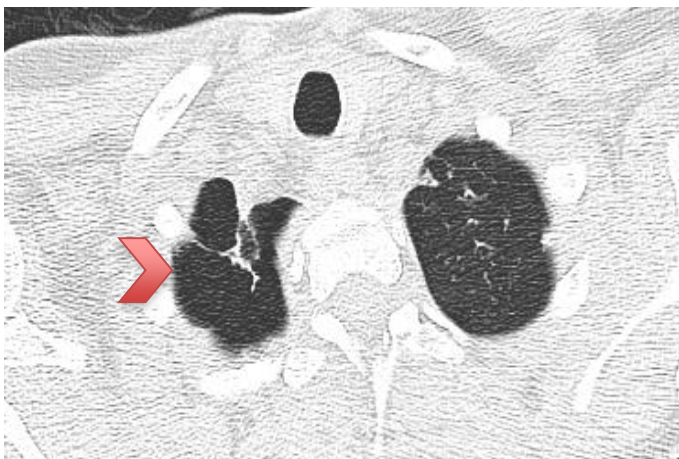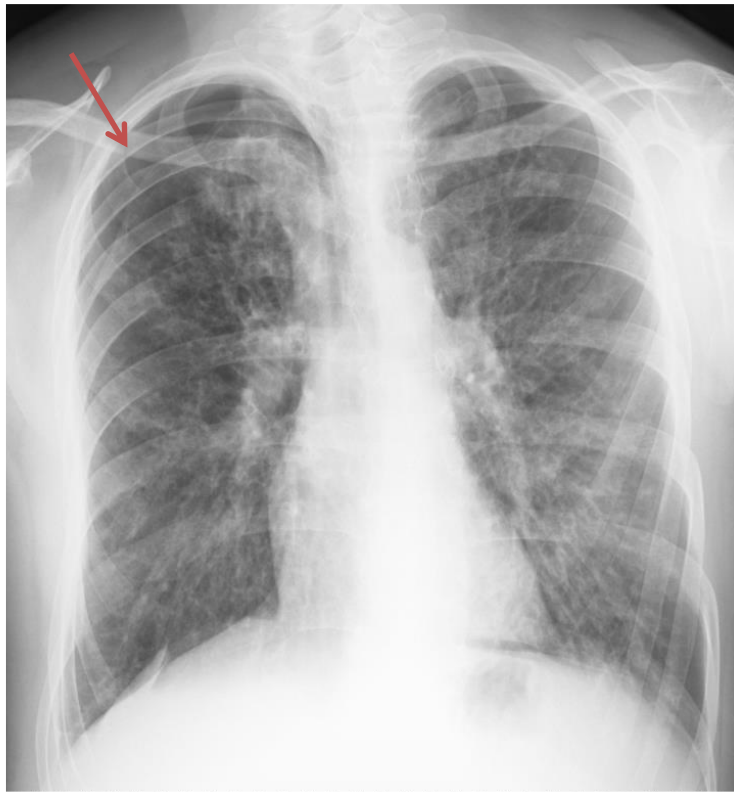




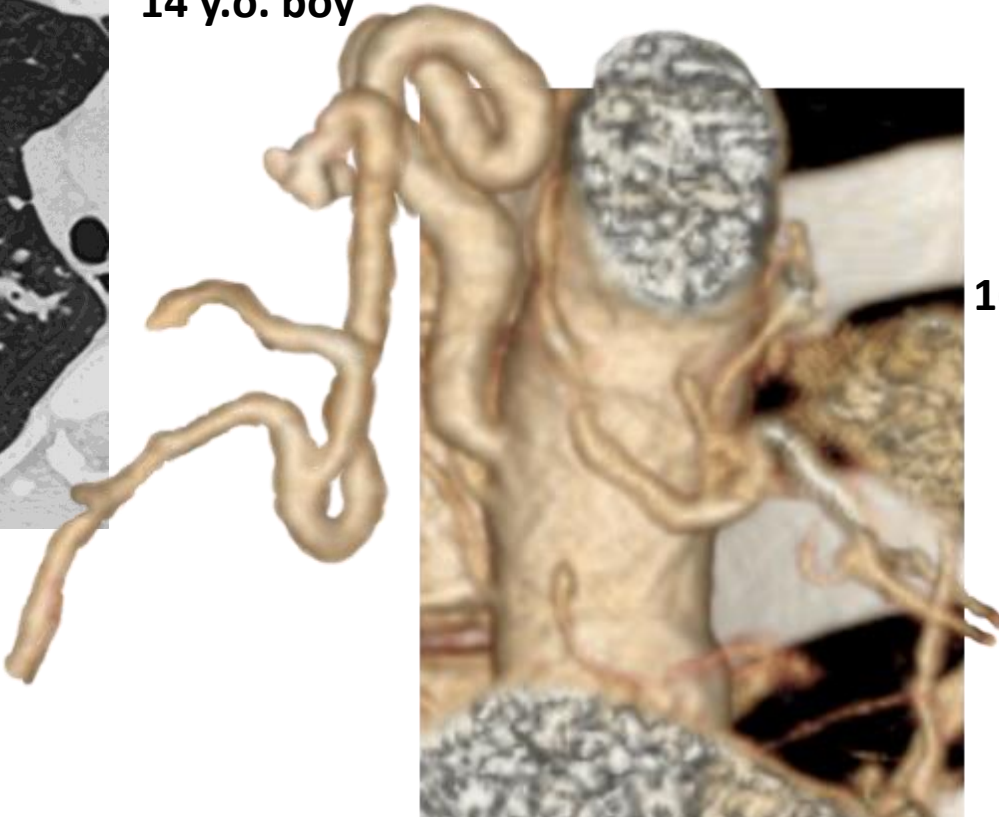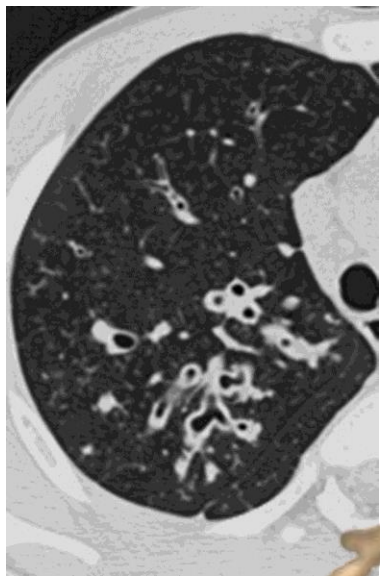


17 y.o. girl

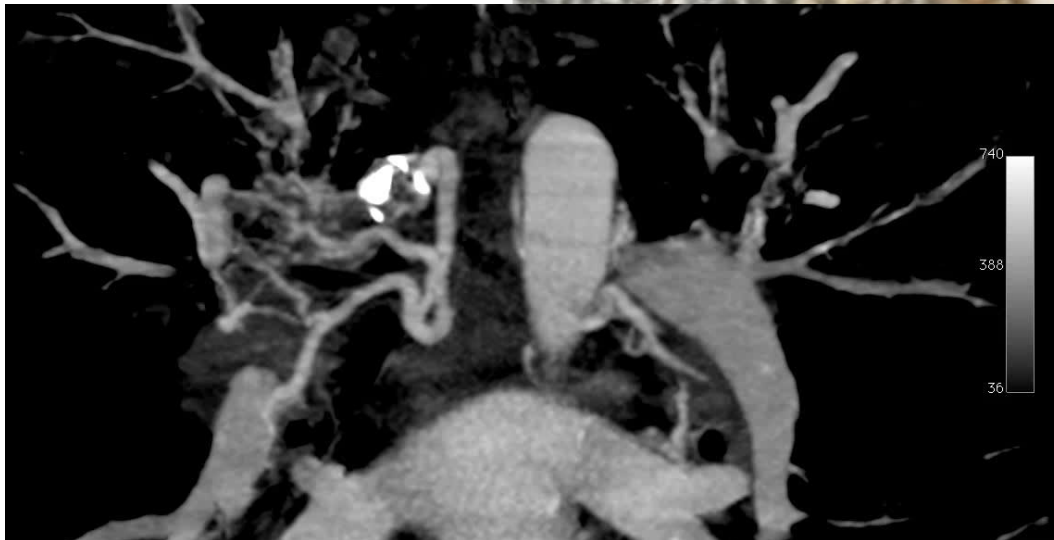
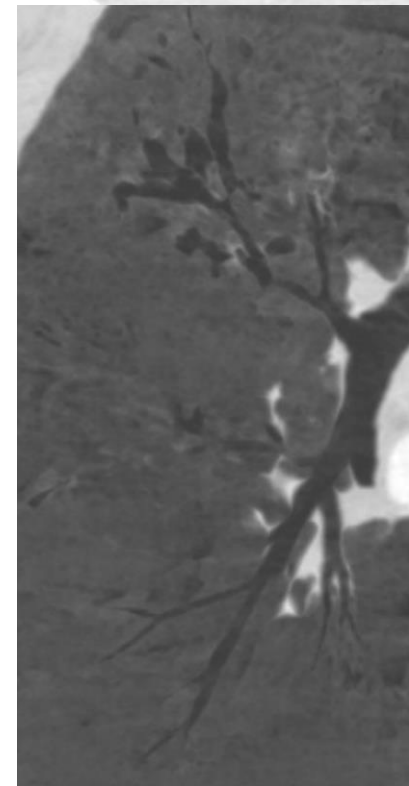
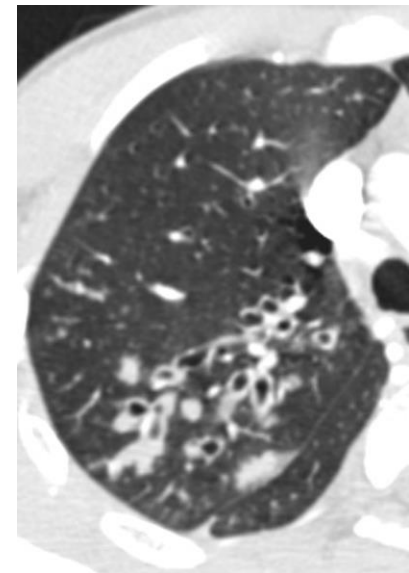




14 y.o. boy



16 y.o. boy





Grazie!

*Fine prima parte...*

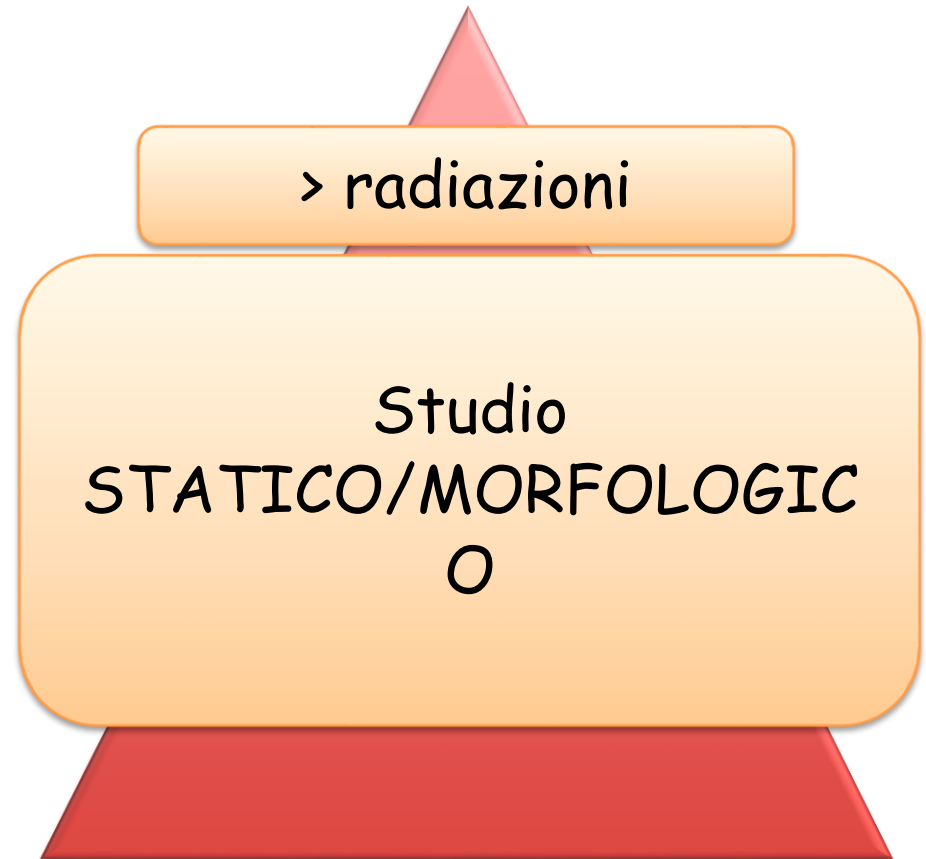
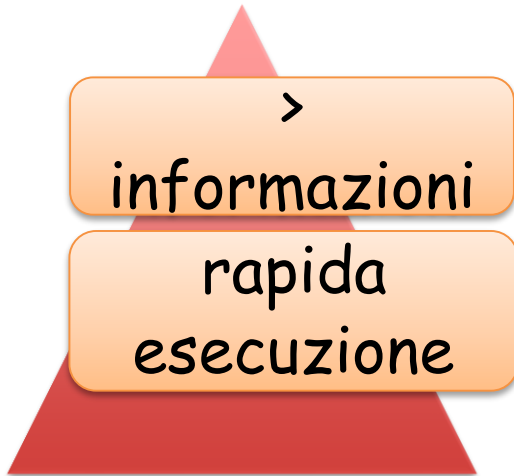
FONDAZIONE IRCCS CA' GRANDA  
OSPEDALE MAGGIORE POLICLINICO

Sistema Sanitario  Regione  
Lombardia



# TC: PRO-CONTRO



# RM: PRO-CONTRO

NO radiazioni

Studio  
morfologico/FUNZION  
ALE

> durata esame

< informazioni (?)

Caratteristiche del  
polmone

# RM recente utilizzo



## 1. Carenza di protoni:

- la qualità dell'immagine dipende dalla densità dei protoni nel tessuto analizzato
- il polmone ha una bassa densità di protoni, perciò il segnale generato è basso

# RM recente utilizzo



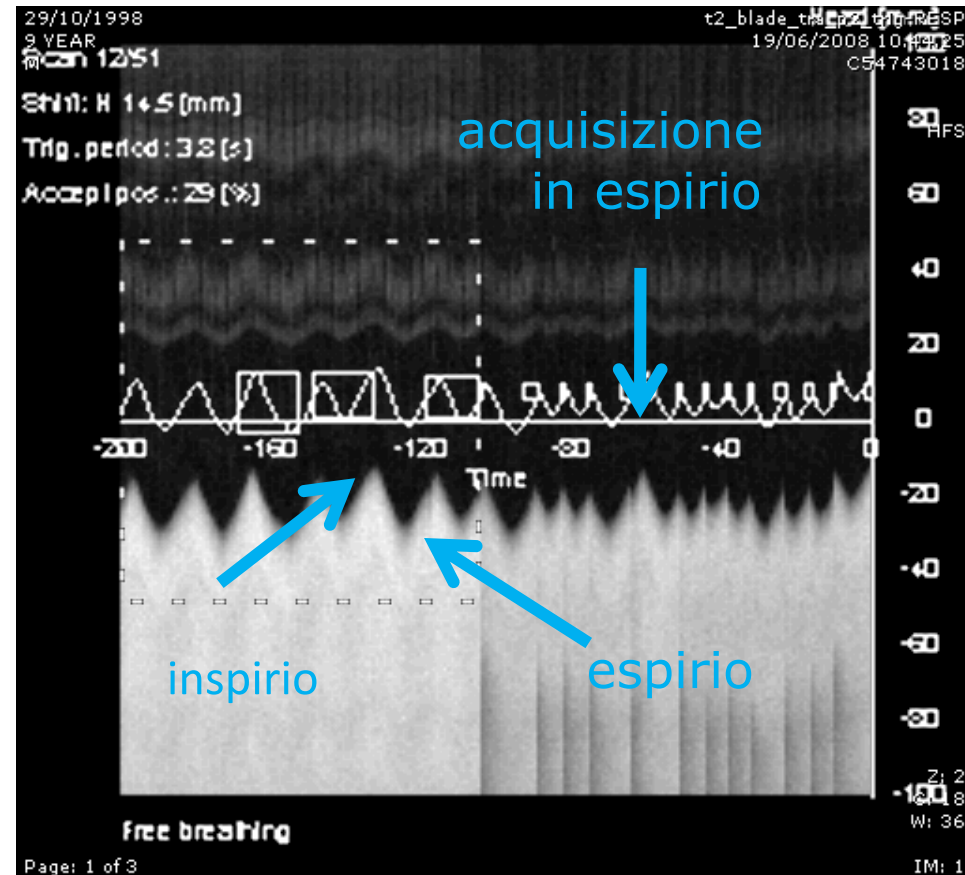
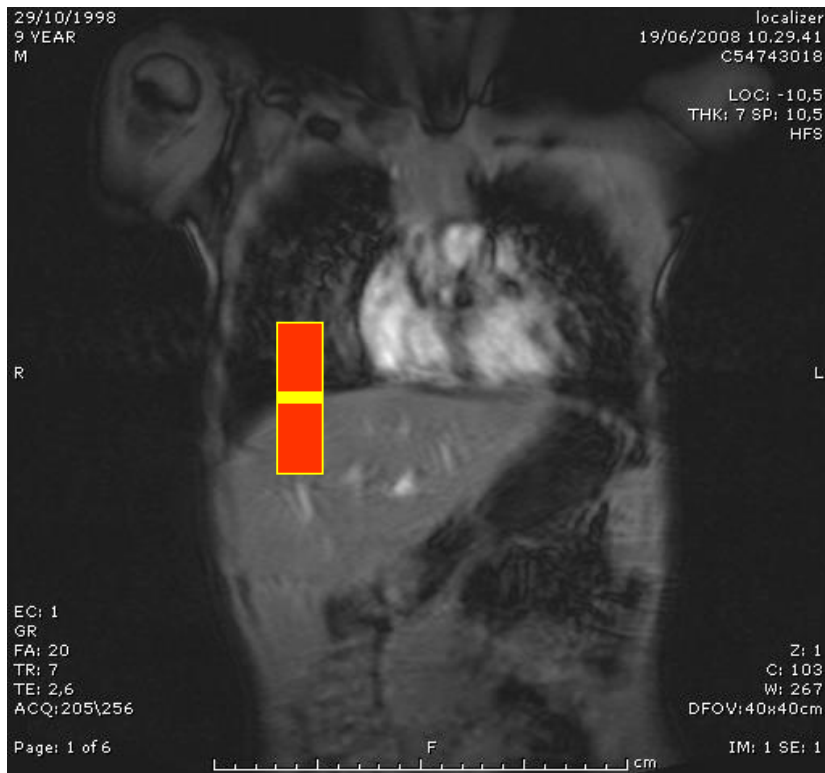## 2. Artefatti da movimento, legati:

- al battito cardiaco
- ai movimenti respiratori





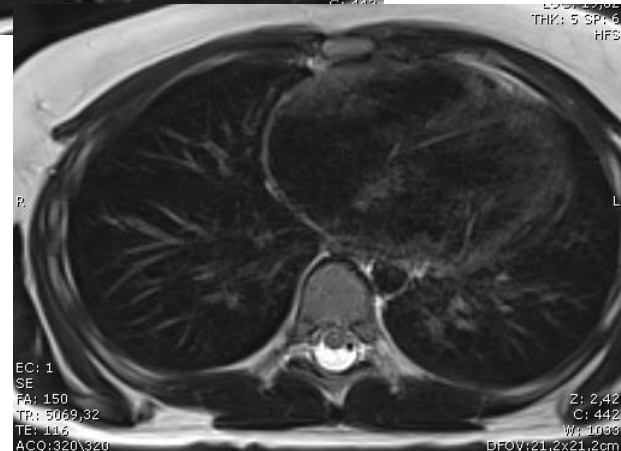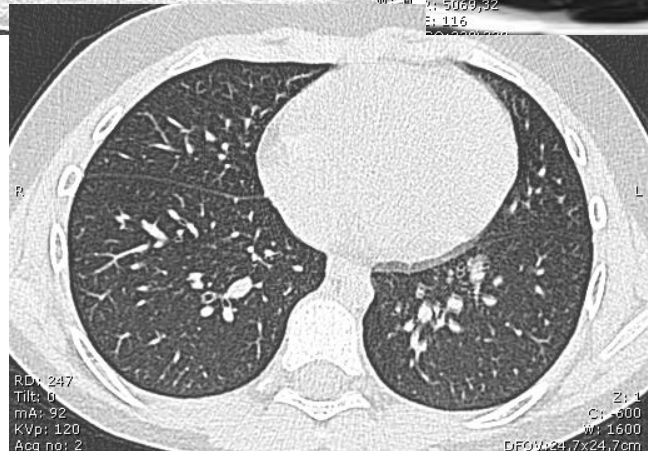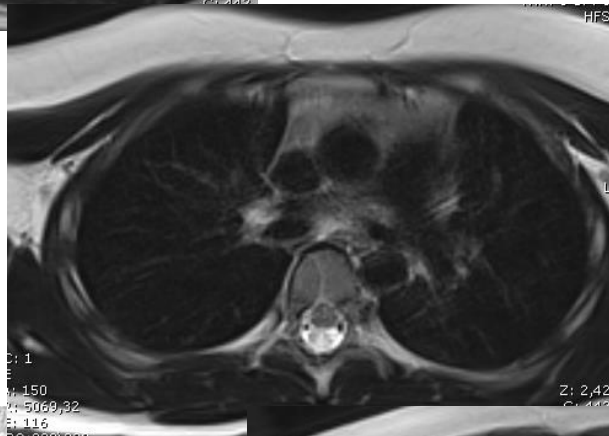
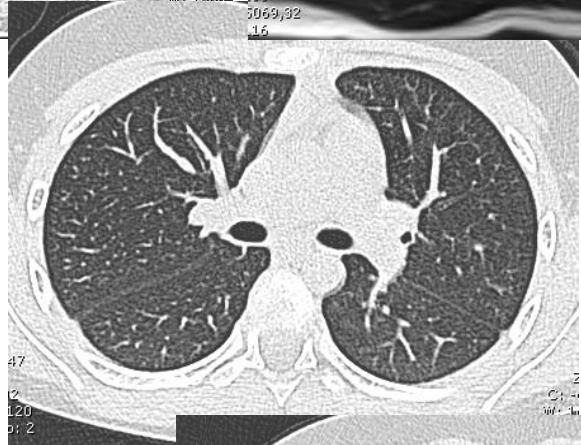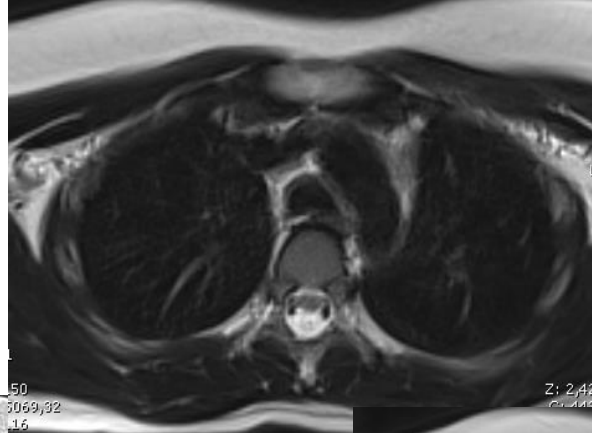
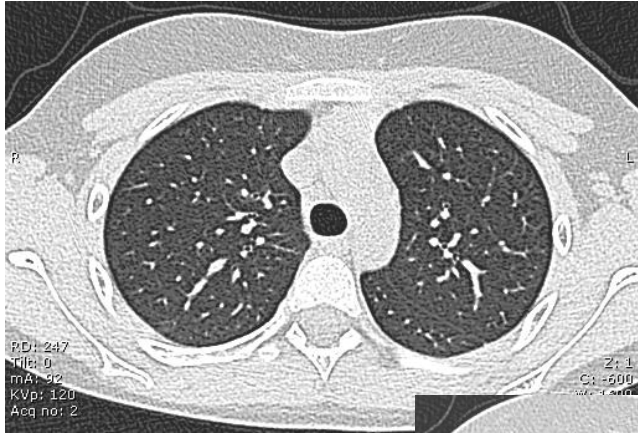- immagini con respiro trattenuto
- immagini ottenute solo in fase di espirio grazie al trigger espiratorio



# QUADRO NEGATIVO

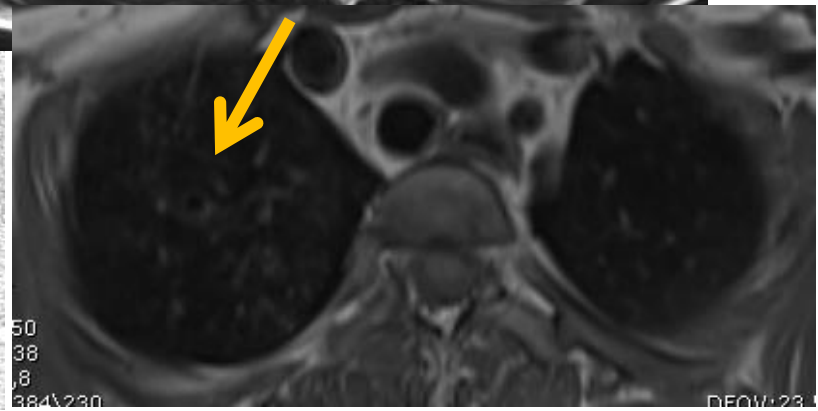
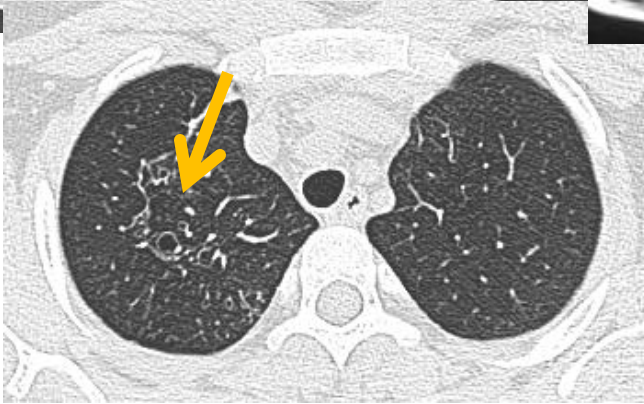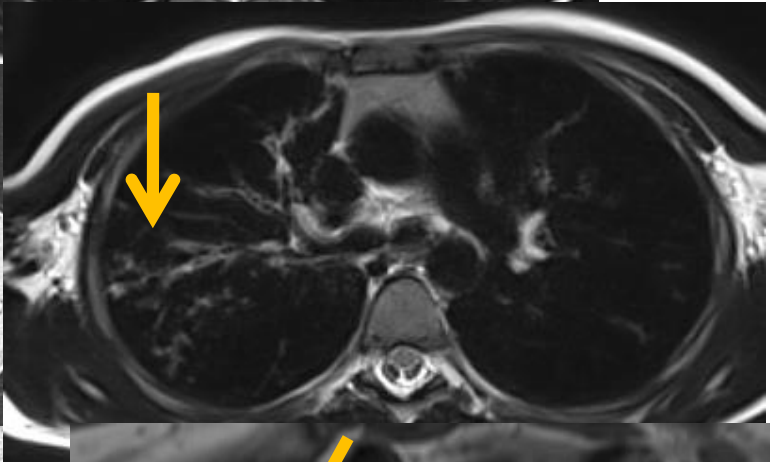
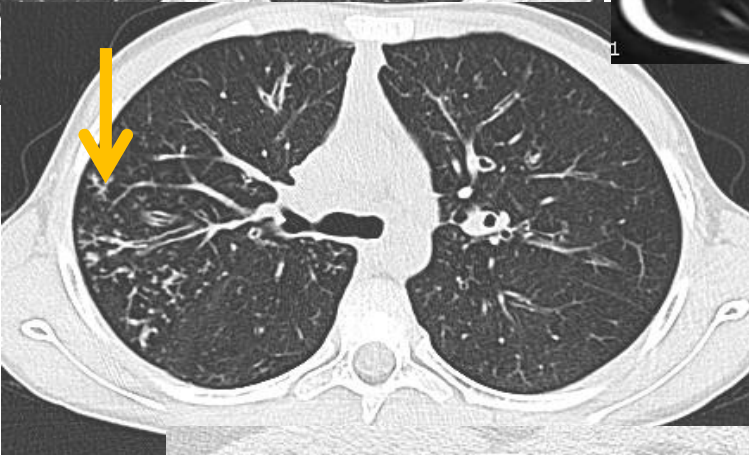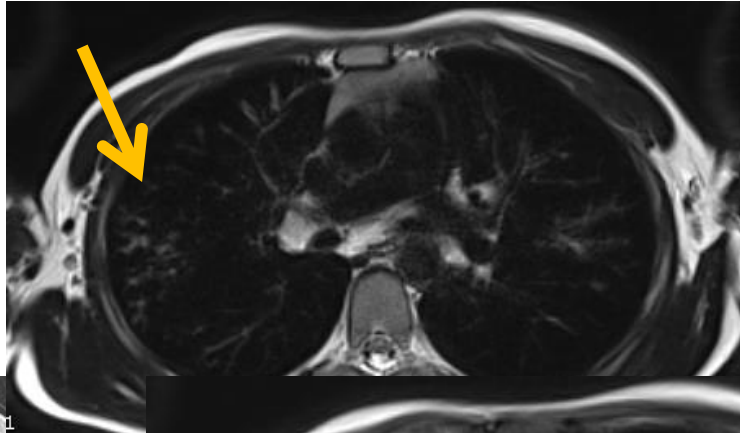
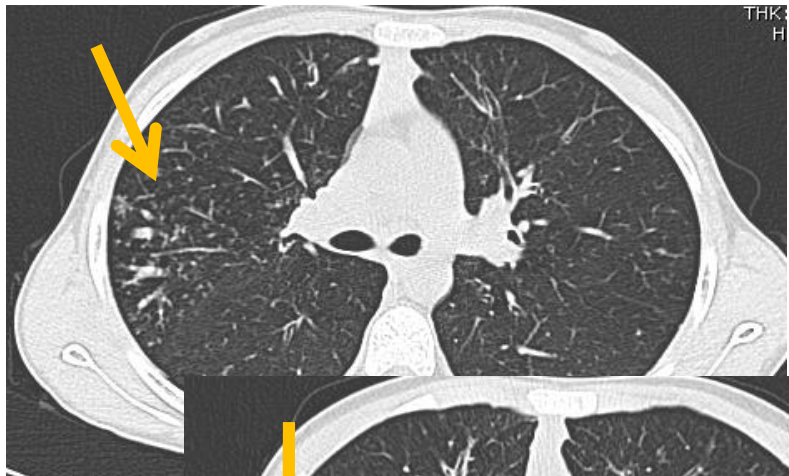Aria: pulmone nero

Vasi/bronchi: TC > RM



# QUADRO POSITIVO

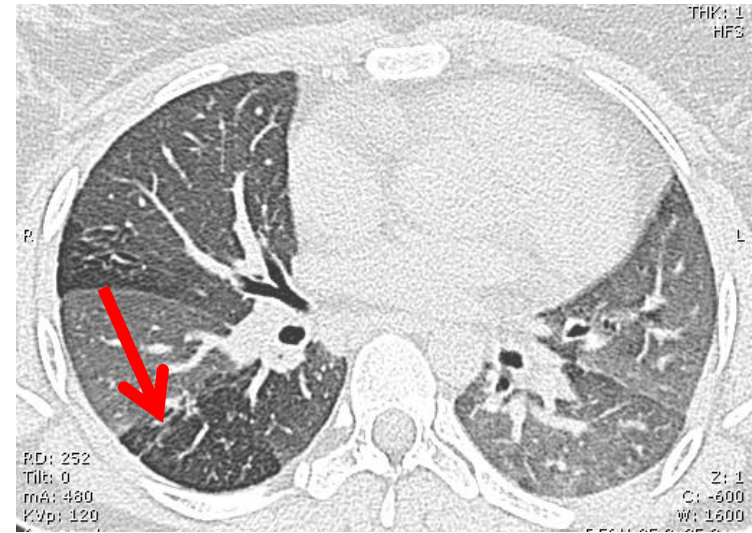
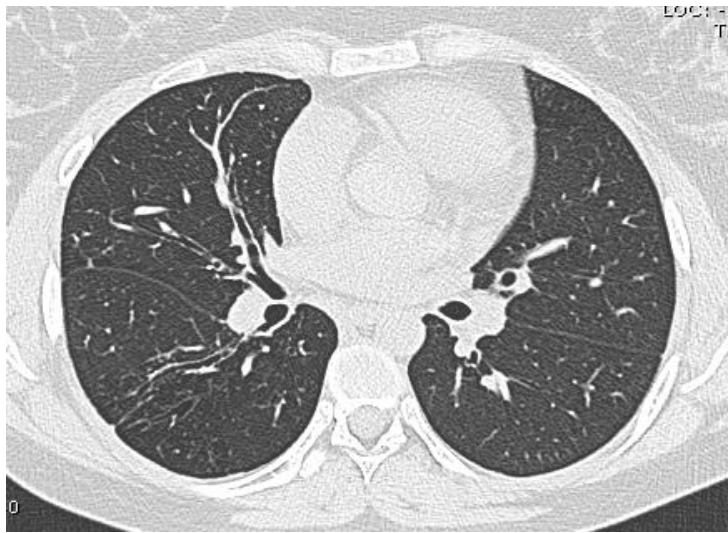
VEDOANCHE ANOMALIE PICCOLE/PERIFERICHE (BRONCHIOLECTASIE SUBPLEURICHE,...)



# ACQUISIZIONE IN ESPIRIO

# AIR TRAPPING

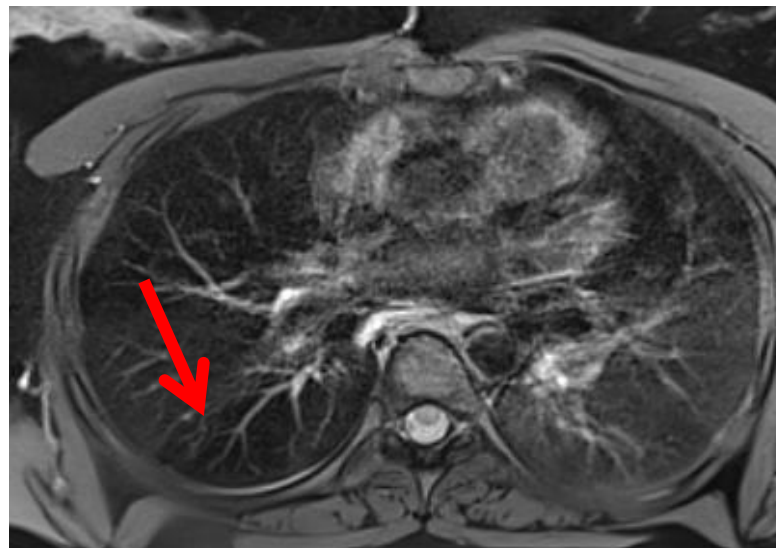
Particolari sequenze RM sembrano individuare le zone di “**air trapping**” in modo sovrapponibile alla TC (work in progress)

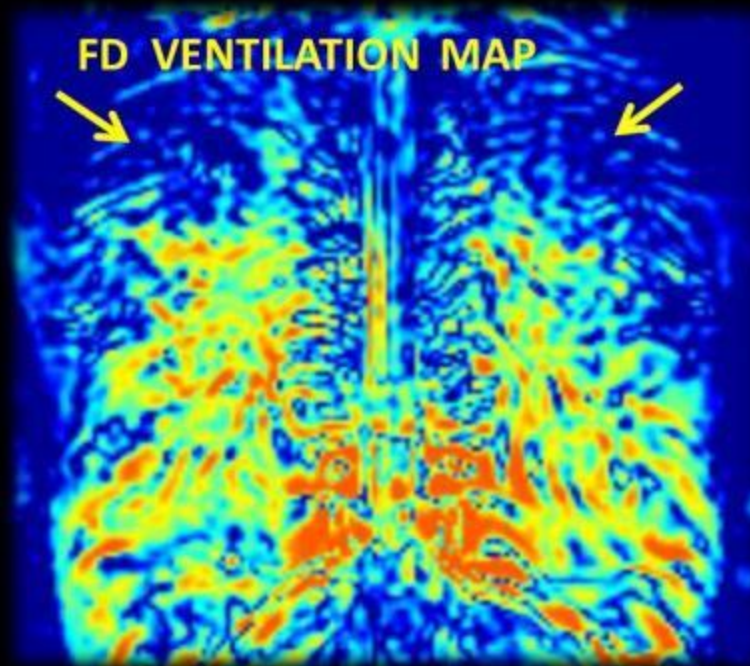
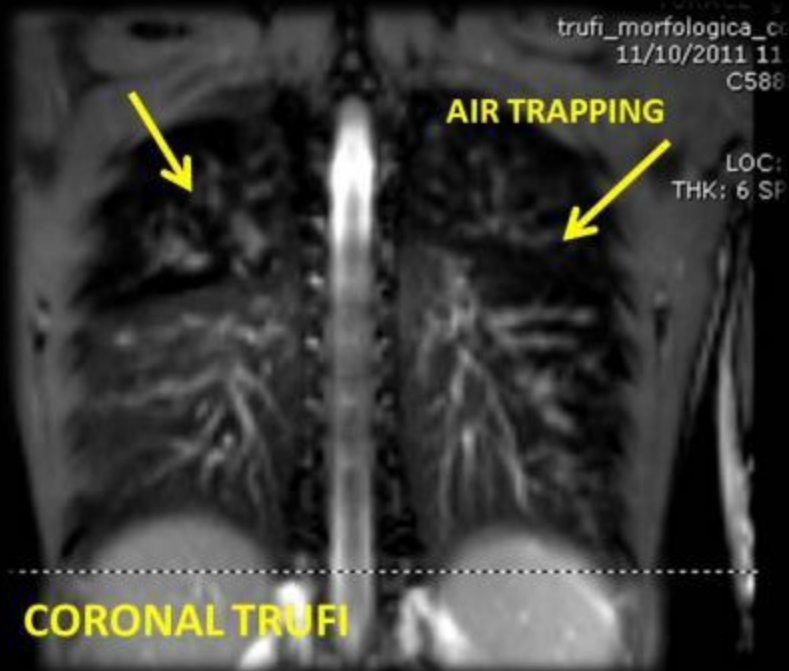


TC INSPIRIO

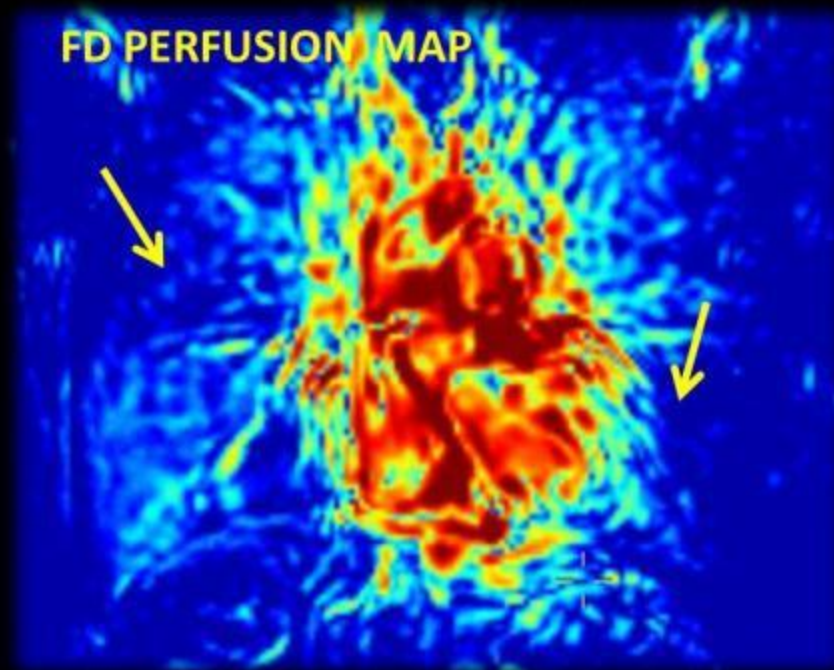
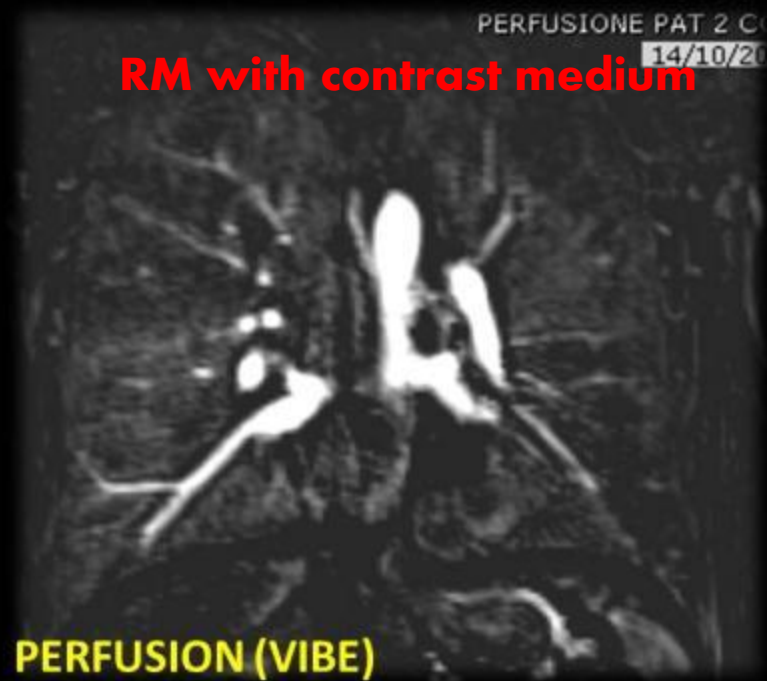
TC ESPIRIO

RM TRUFI  
con spirometro

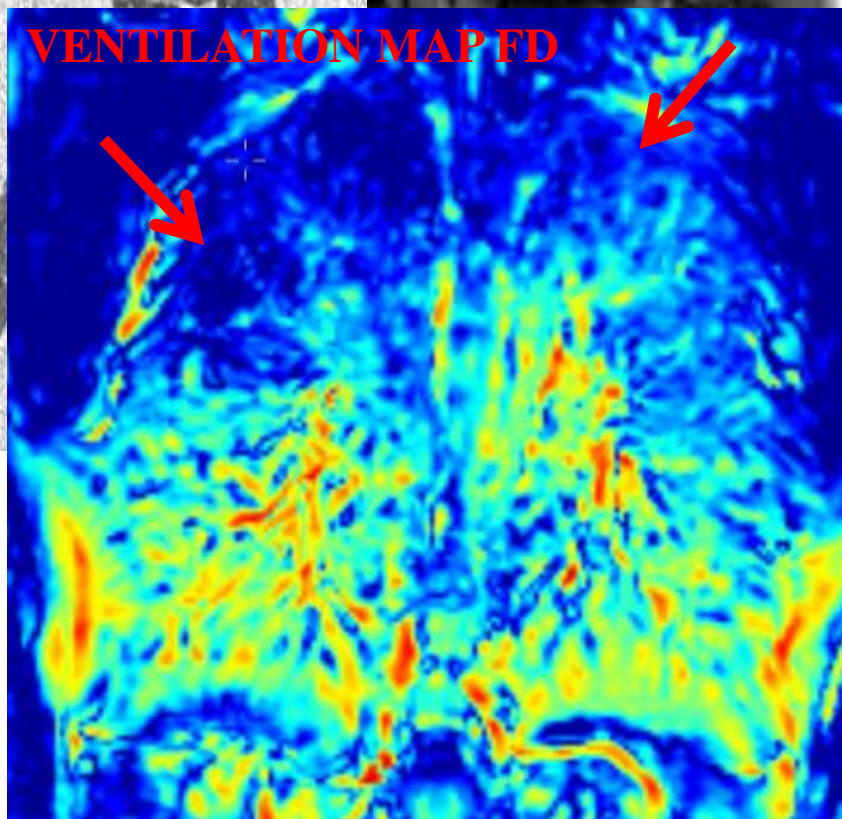
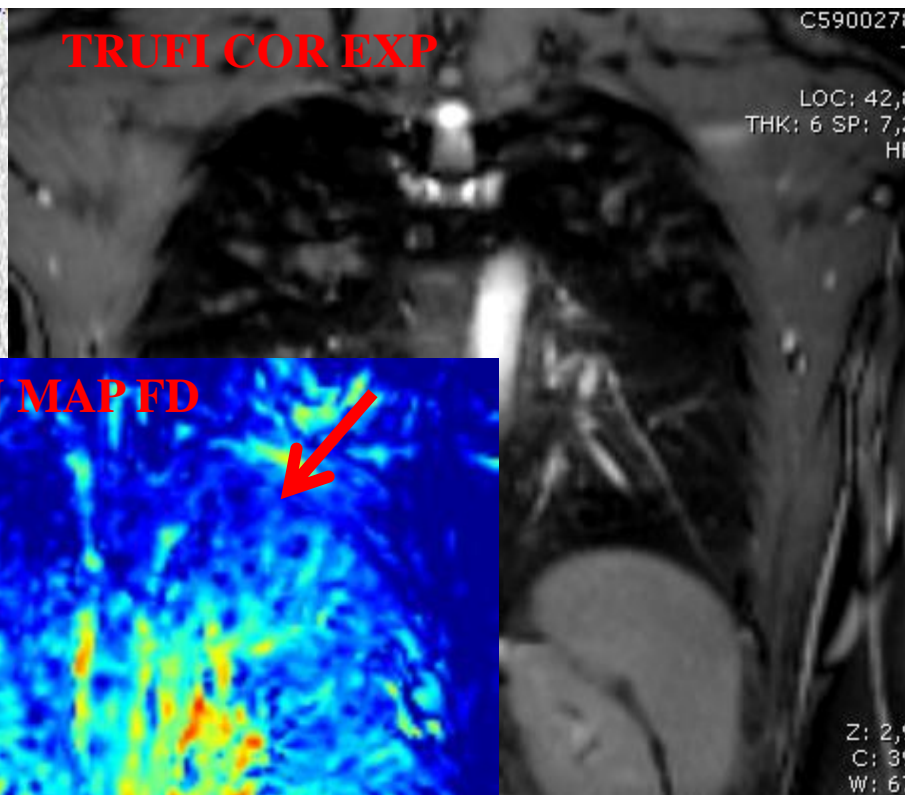
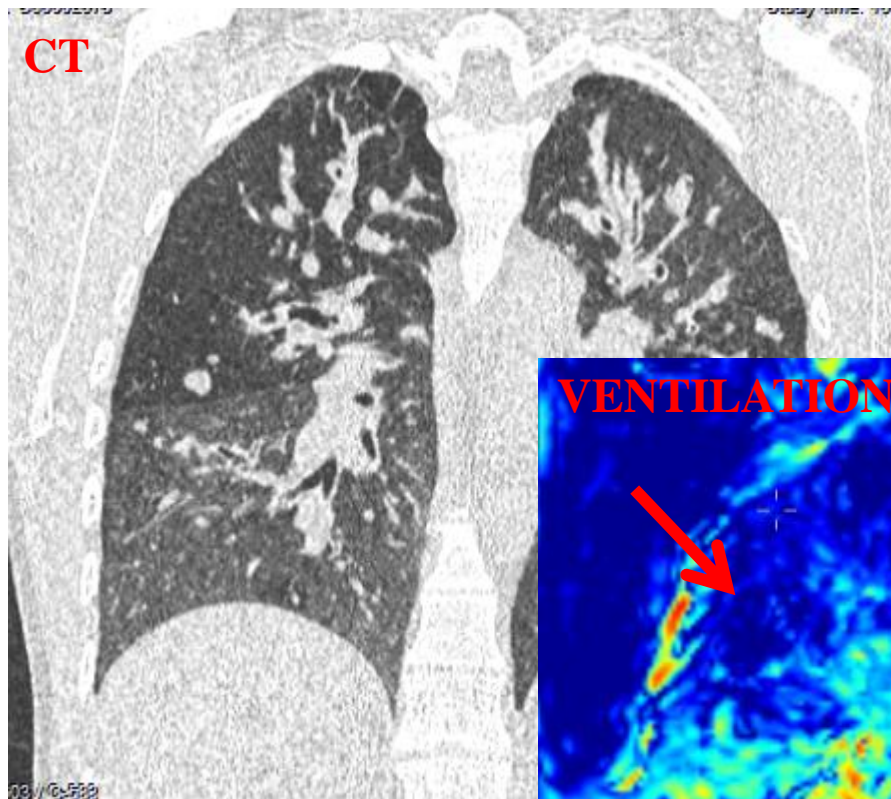




**CF**  
**F 25 y**



# Comparison: CT, TRUFI, FD

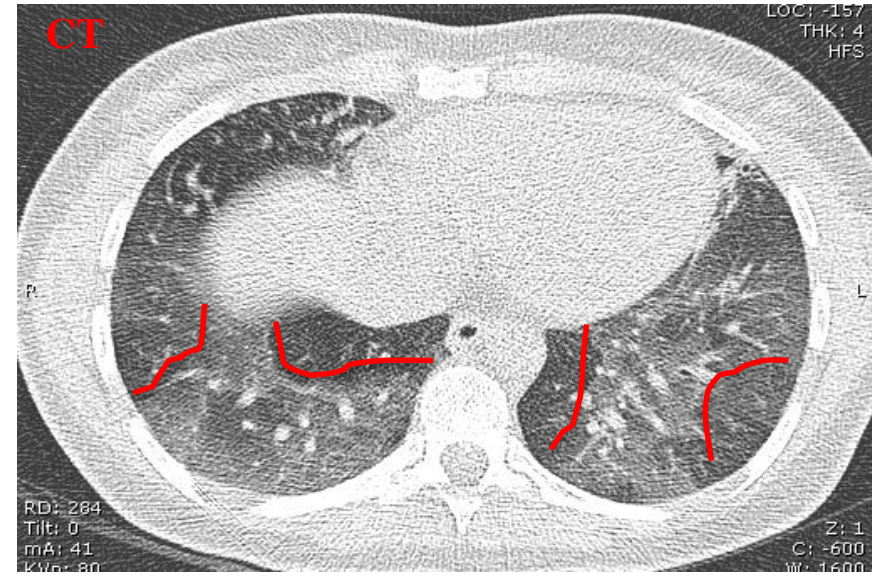


**AIR TRAPPING**

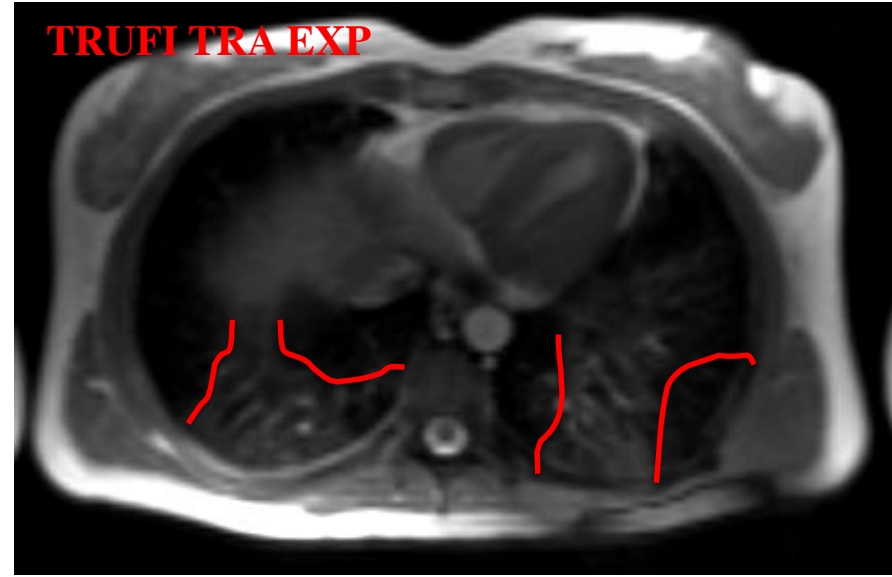


# Comparison: CT, TRUFI

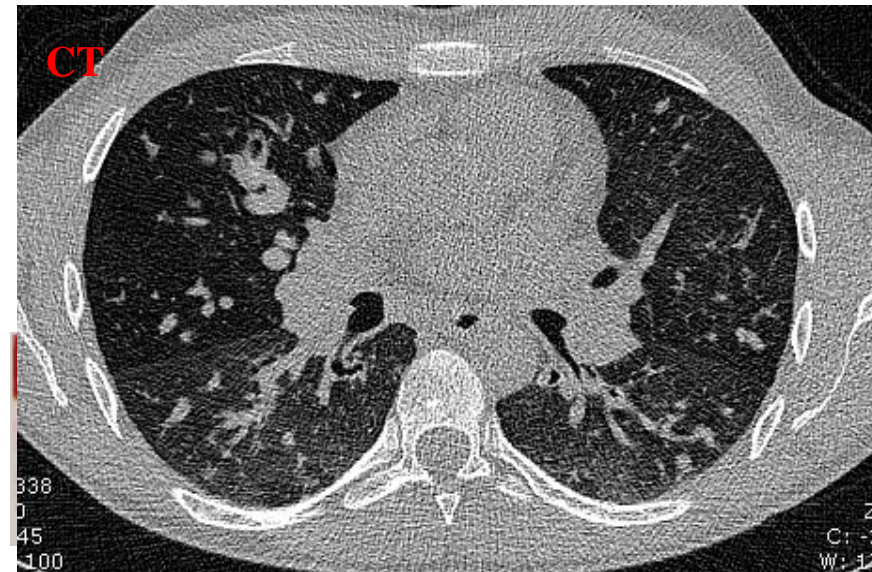
CT



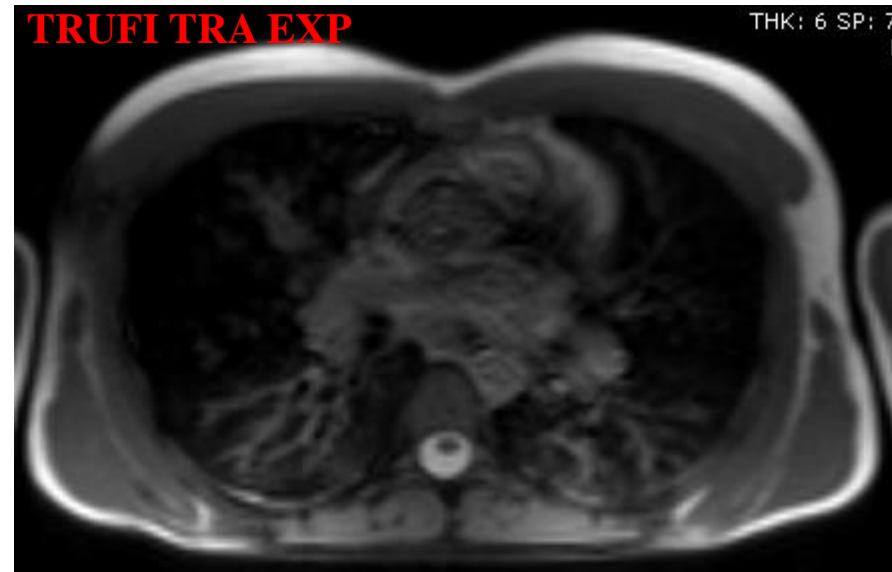
TRUFI TRA EXP



CT



TRUFI TRA EXP



# STUDIO MORFOLOGICO (STATICO)

TC

RX



RM



...but RM is SOMETHING MORE...

- **Studio MORFOLOGICO: TC e RM**

RM ha < dettaglio anatomico nella normalità, ma può individuare la patologia come la TC

- **AIR TRAPPING: TC e RM**

RM potrebbe individuare le zone dove si verifica intrappolamento aereo come la TC

- **Studio FUNZIONALE...**

# STUDIO FUNZIONALE (DINAMICO)

TC


RM



RM

TC

**Studio FUNZIONALE...**



**DWI:**  
**Diffusion Weighted Imaging**

# RM DIFFUSION



Sfruttando il movimento delle molecole di acqua extracellulare si pone l'obiettivo di distinguere le zone di **flogosi attiva** dalle zone di **deposito di muco**



dove c'è flogosi ci sono più cellule infiammatorie e quindi < possibilità di movimento



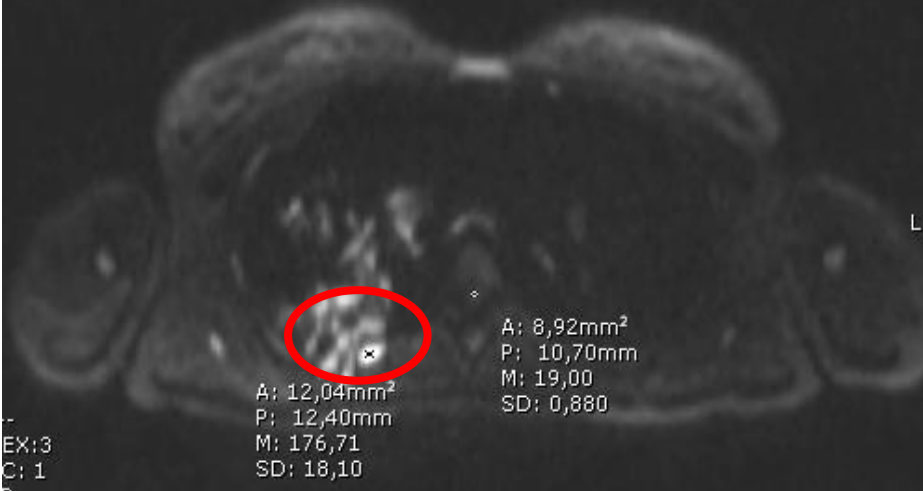
Il segnale decade meno, perciò rimane più iperintenso (bianco)



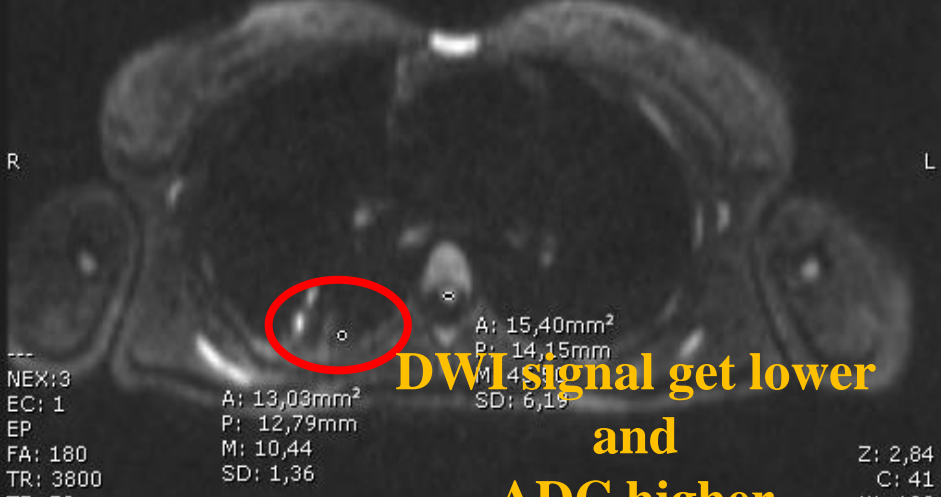
# DWI, ADC images

DWI b=800 sec/mm<sup>2</sup>  
Pre antibiotic

LOC: 49,57  
THK: 6 SP: 7,80  
HFS

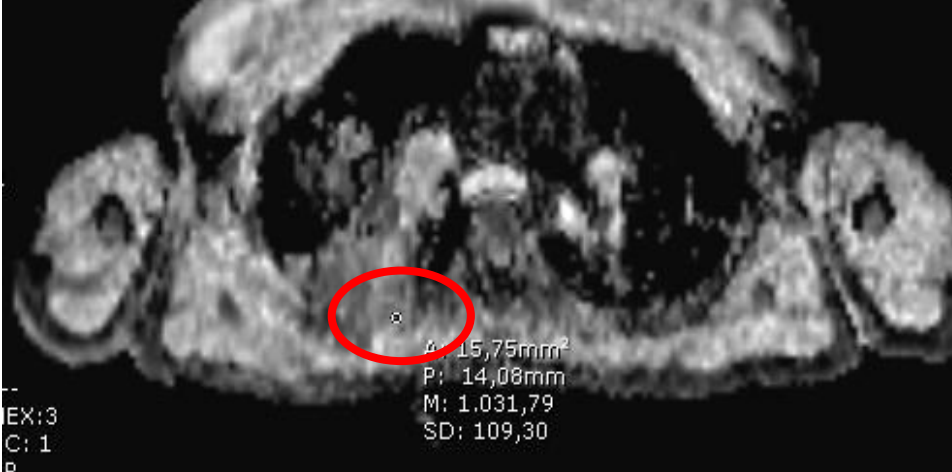

DWI b=800 sec/mm<sup>2</sup>  
Post antibiotic

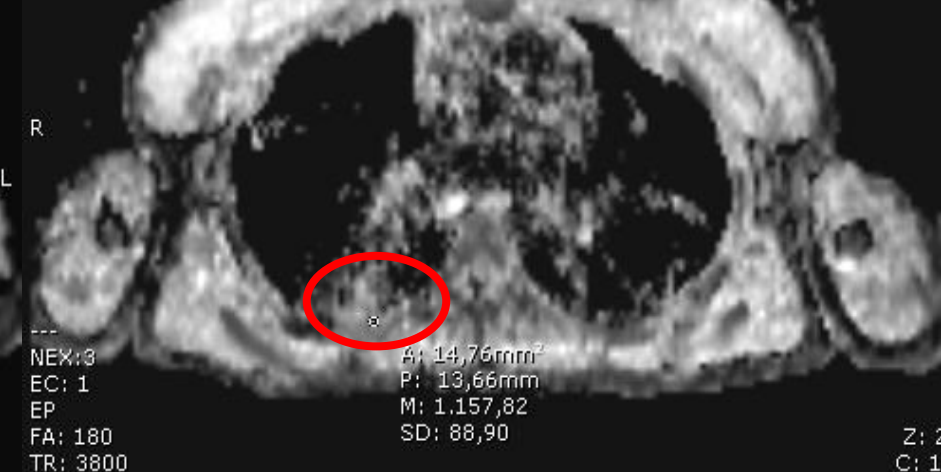


DWI signal get lower  
and  
ADC higher

ADC map  
Pre antibiotic

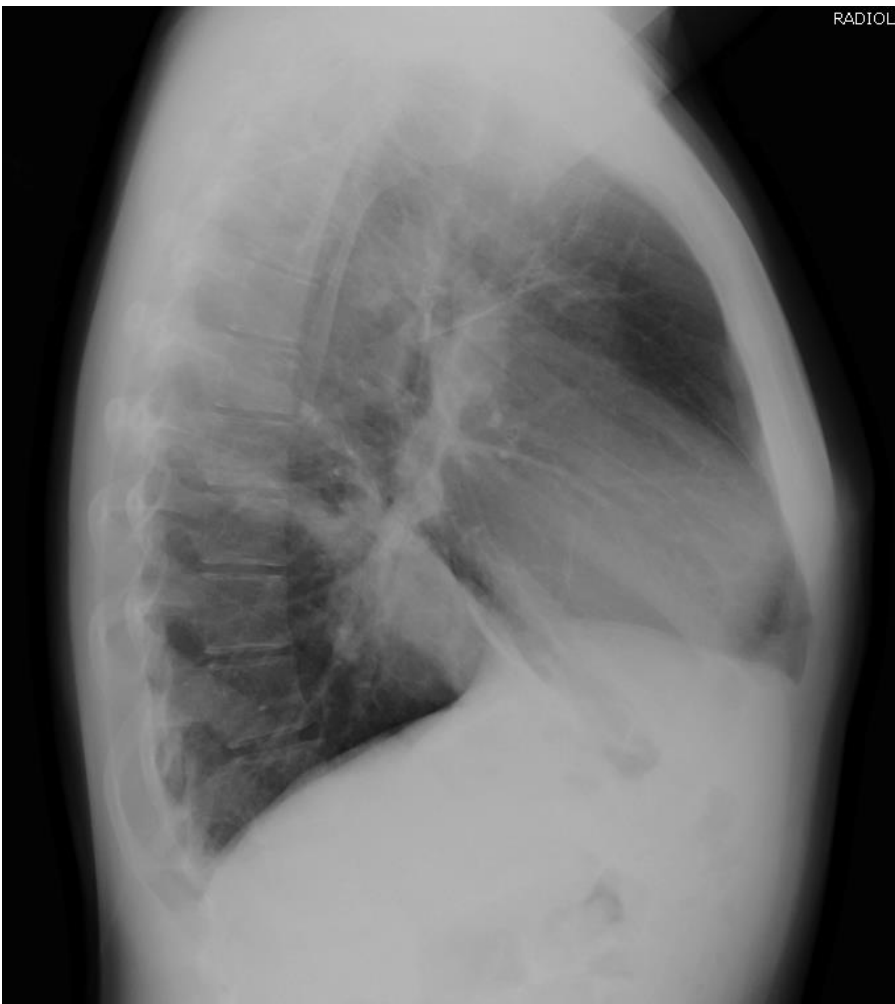

ADC map  
Post antibiotic

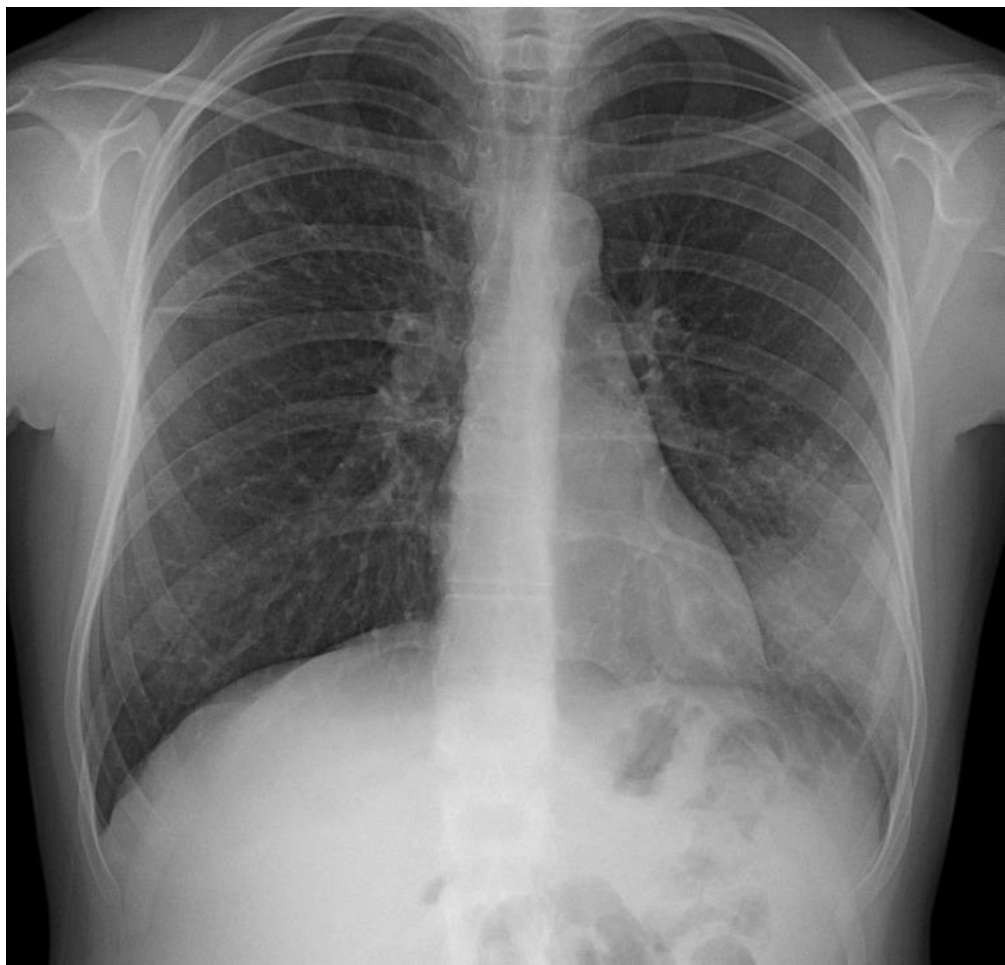




# Chest X-RAY

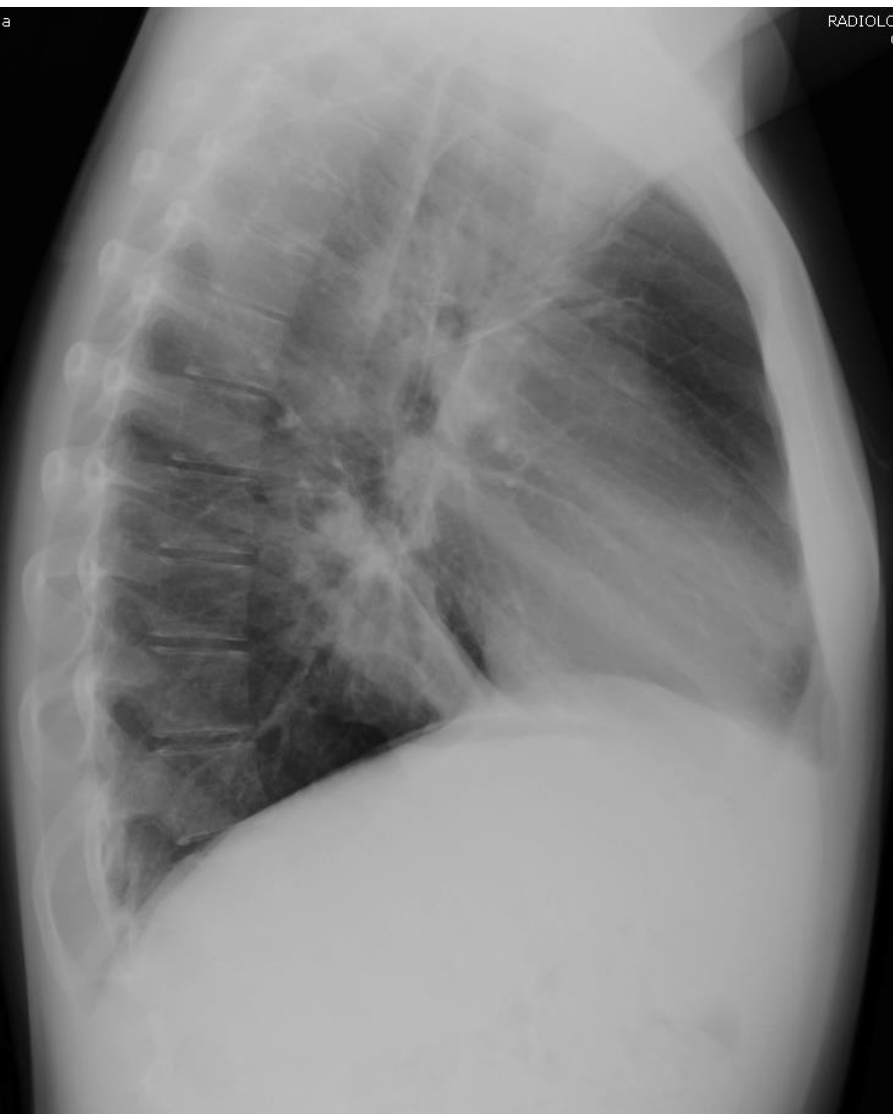

8 agosto 2012

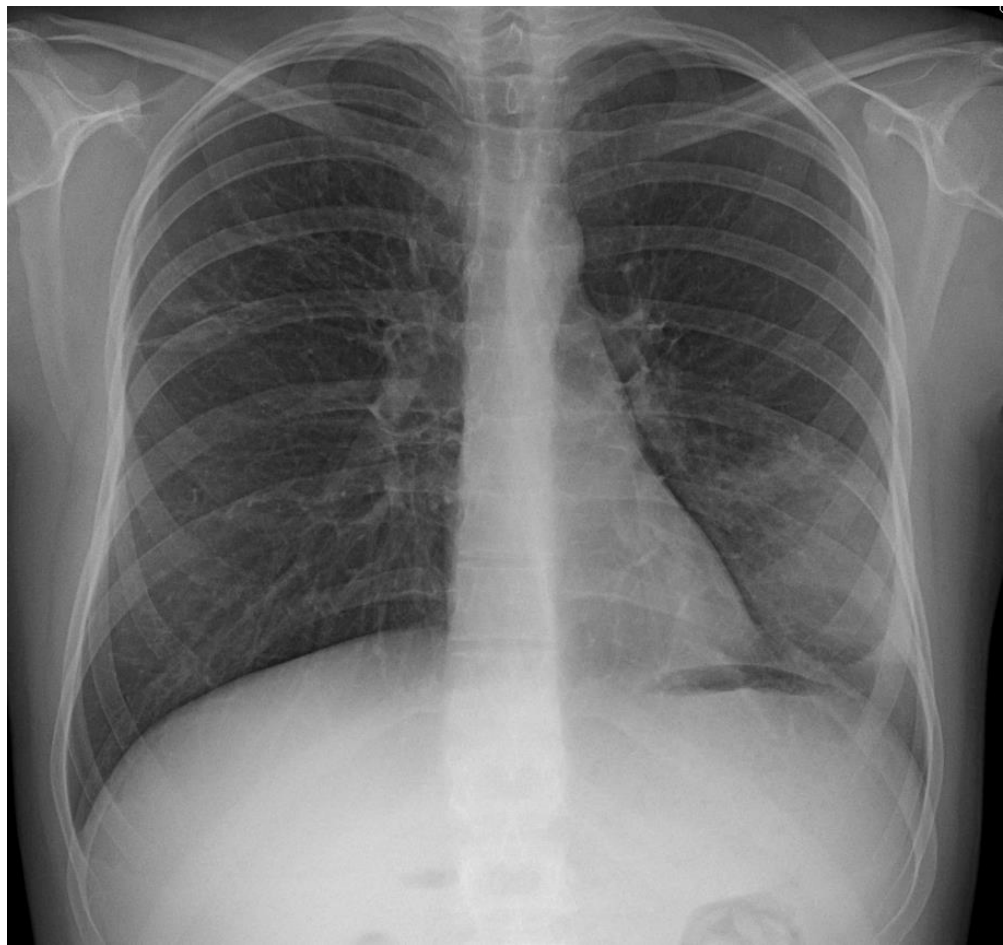



# Chest X-RAY



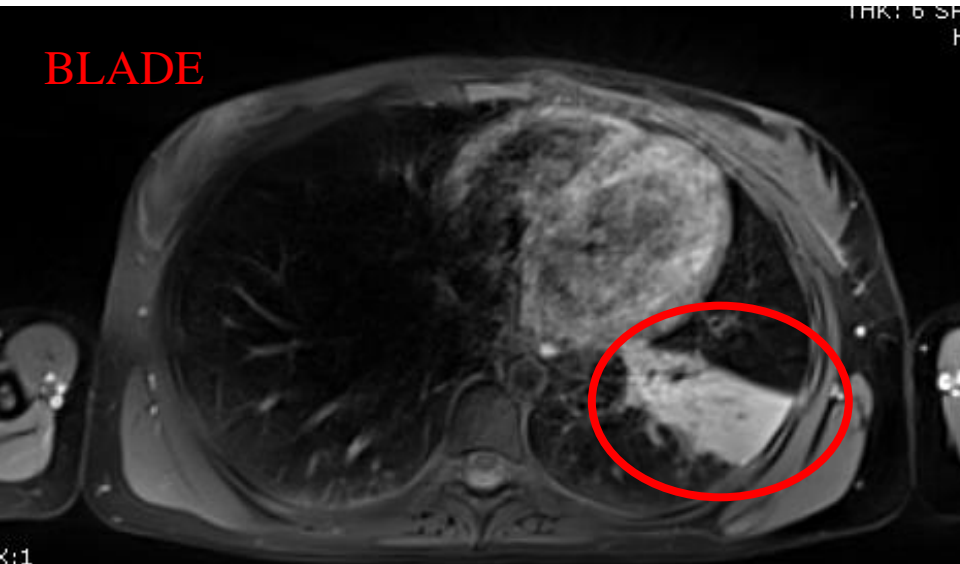
22 agosto 2012  
(dopo 1° trattamento)



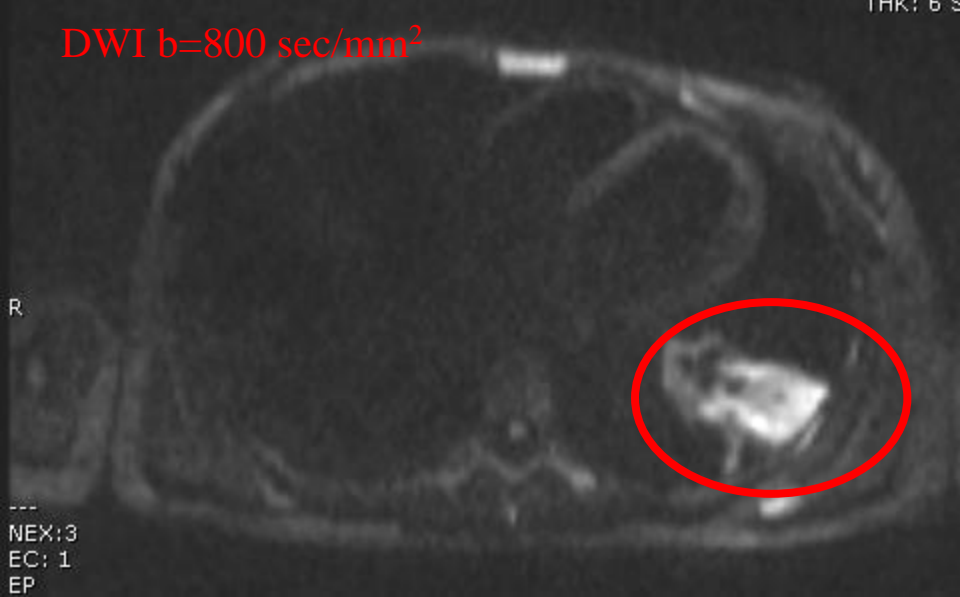

# 1° Examination before antibiotic treatment

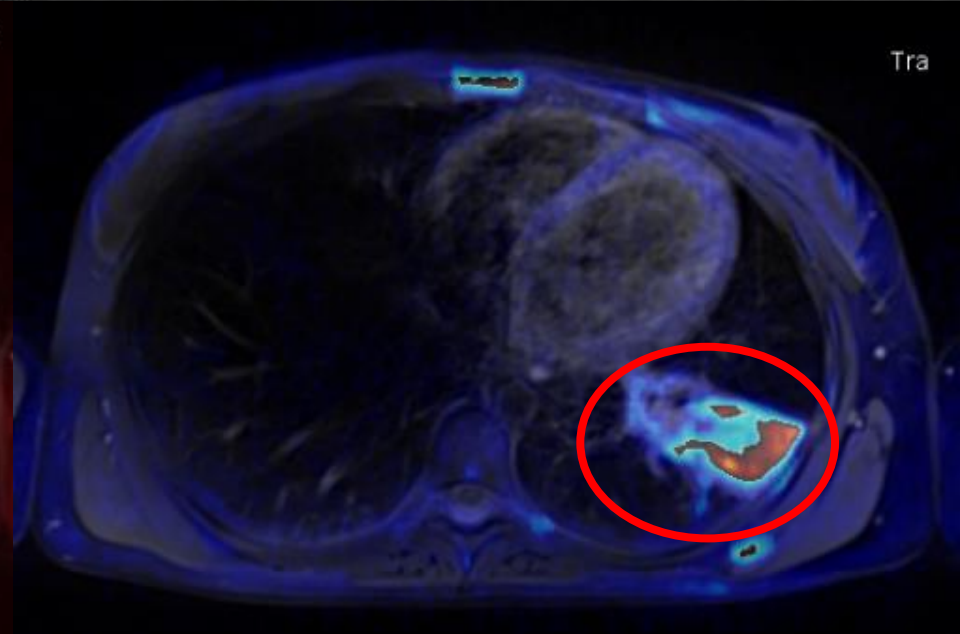
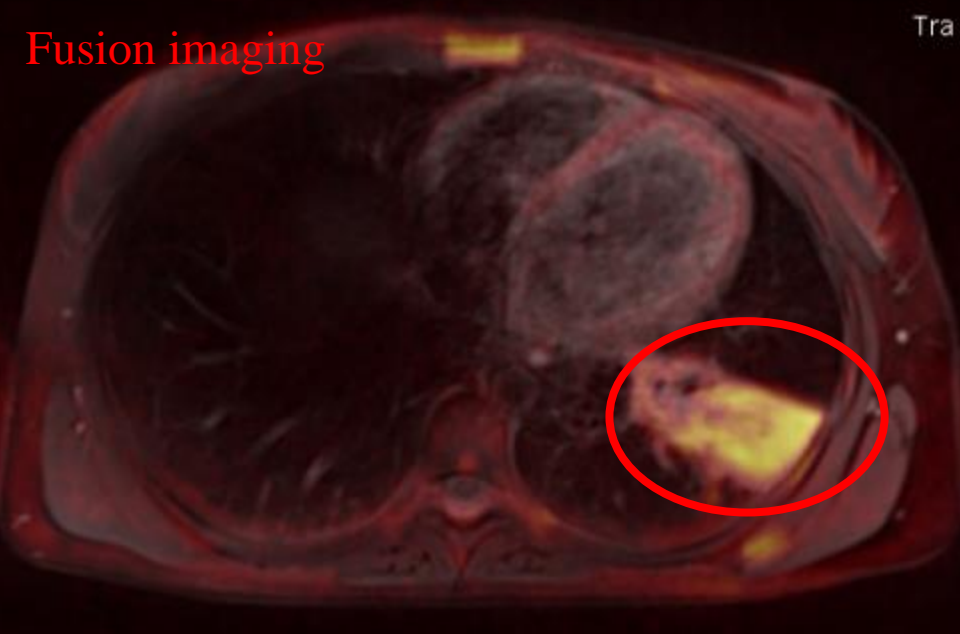
BLADE



DWI b=800 sec/mm<sup>2</sup>



Fusion imaging



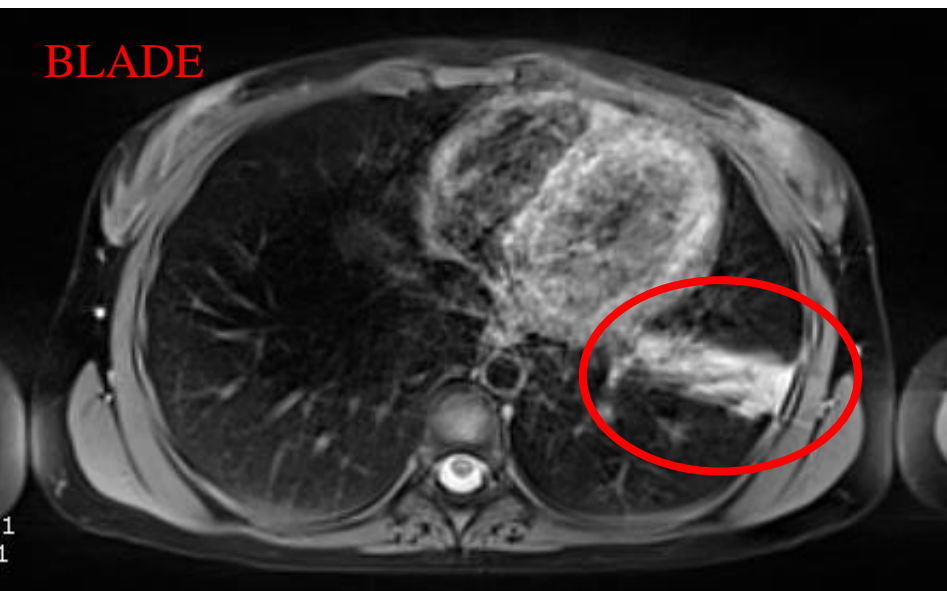


dopo trattamento

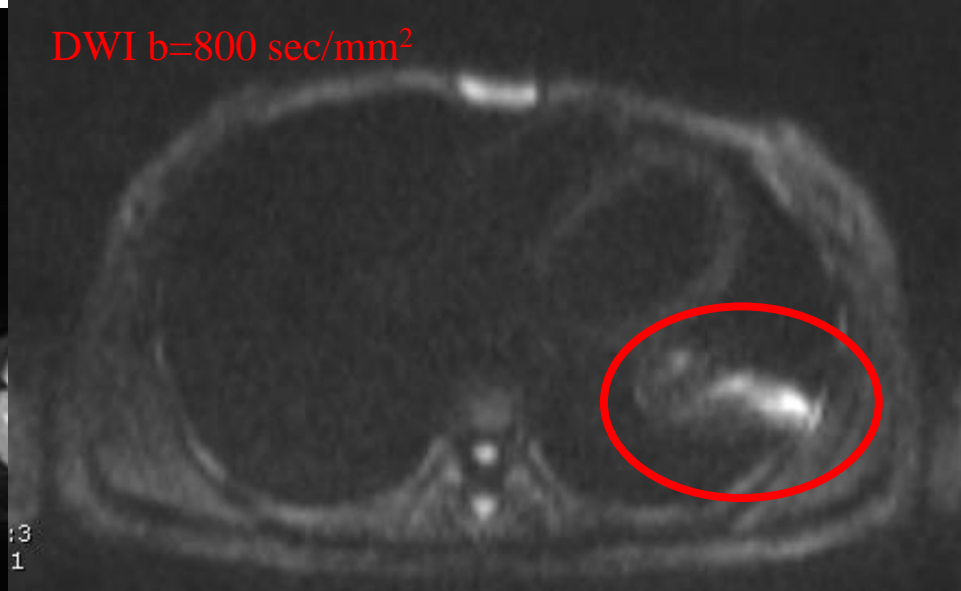

## 2° Examination after antibiotic treatment (3 weeks later)

BLADE

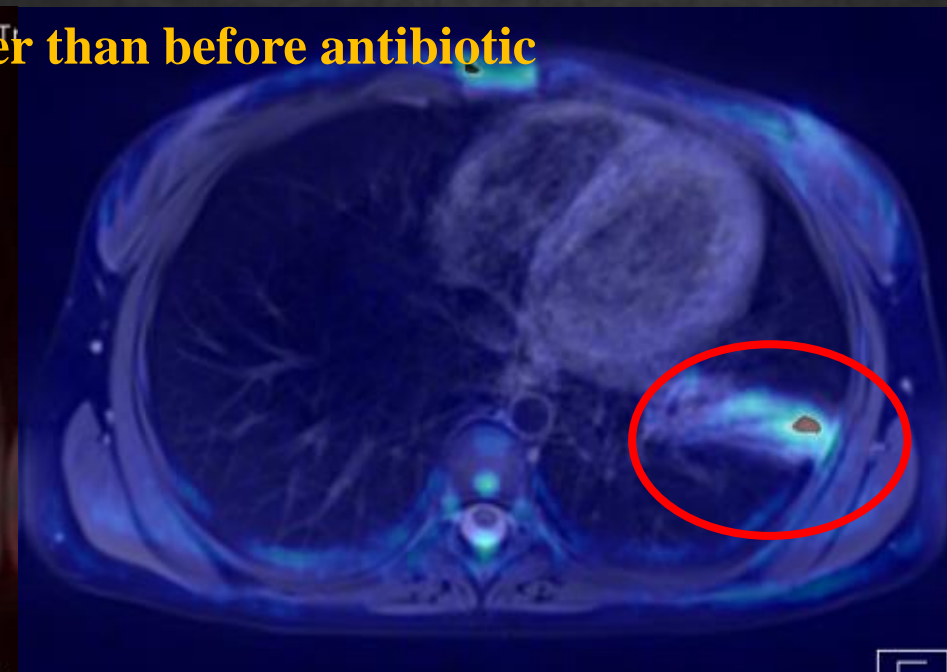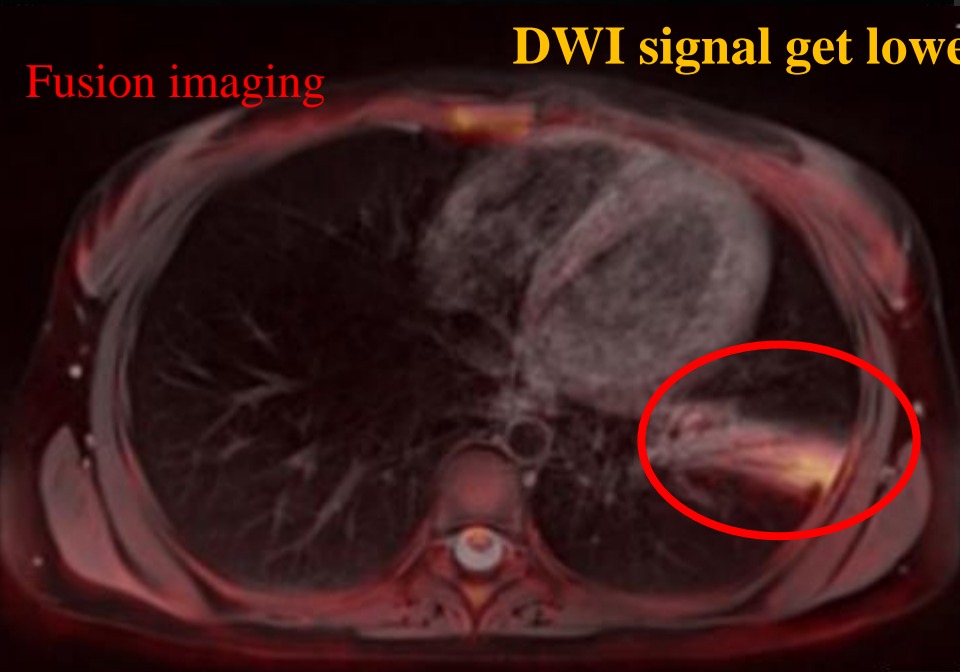


DWI b=800 sec/mm<sup>2</sup>



DWI signal get lower than before antibiotic

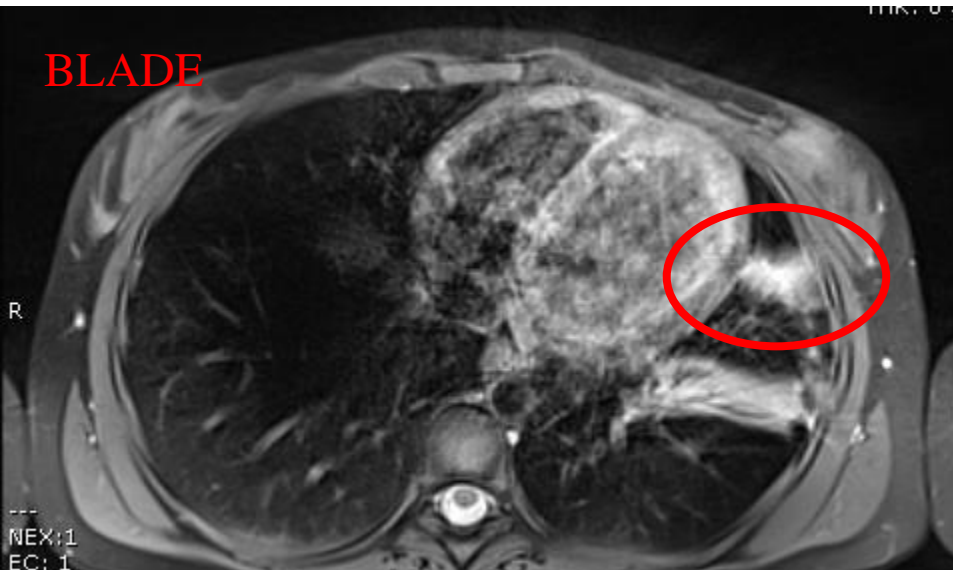
Fusion imaging



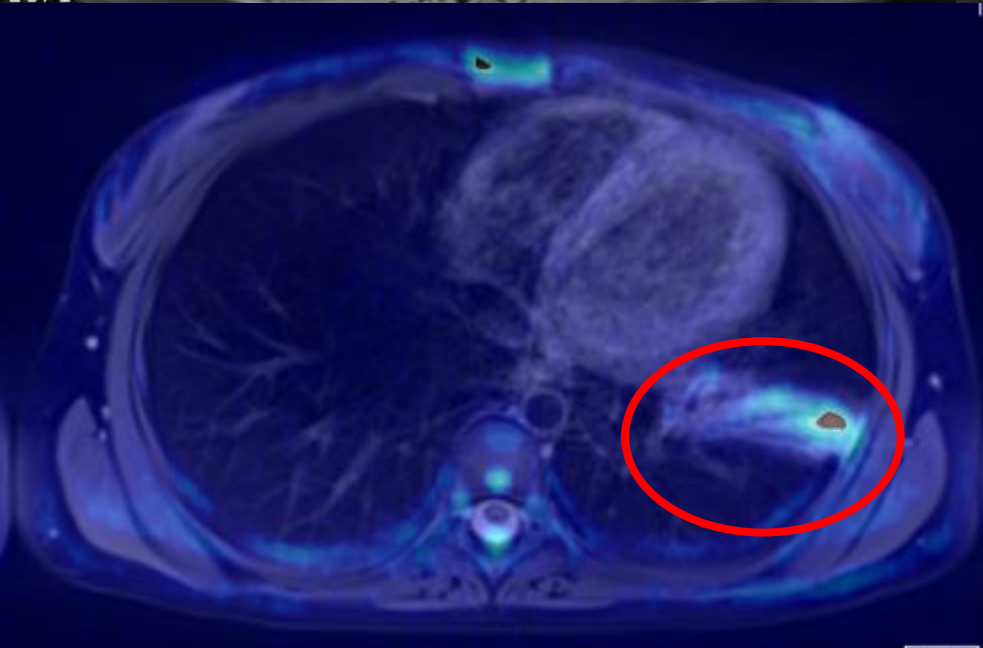
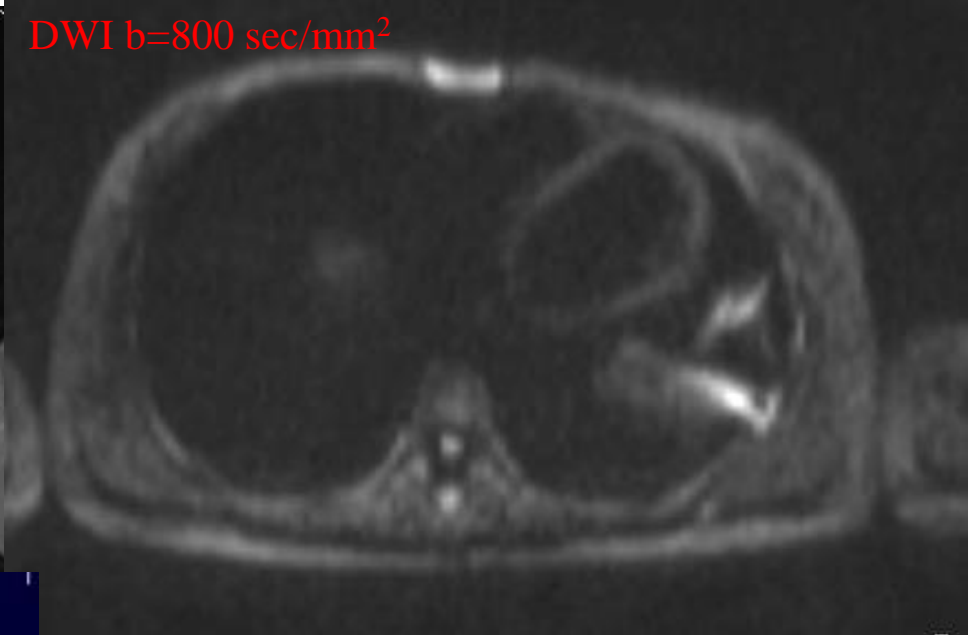


# 3° Examination after antibiotic treatment (5 weeks later)

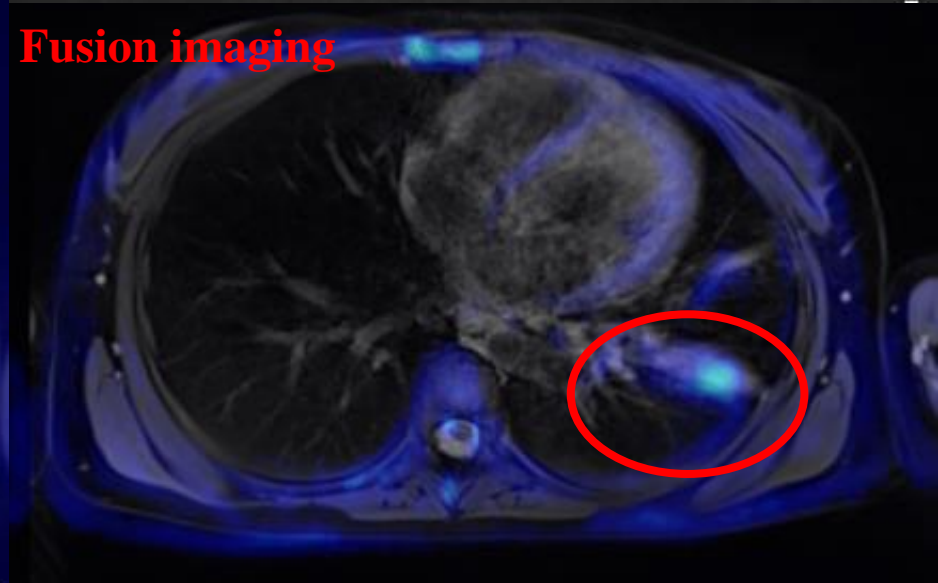
**BLADE**



**DWI b=800 sec/mm<sup>2</sup>**



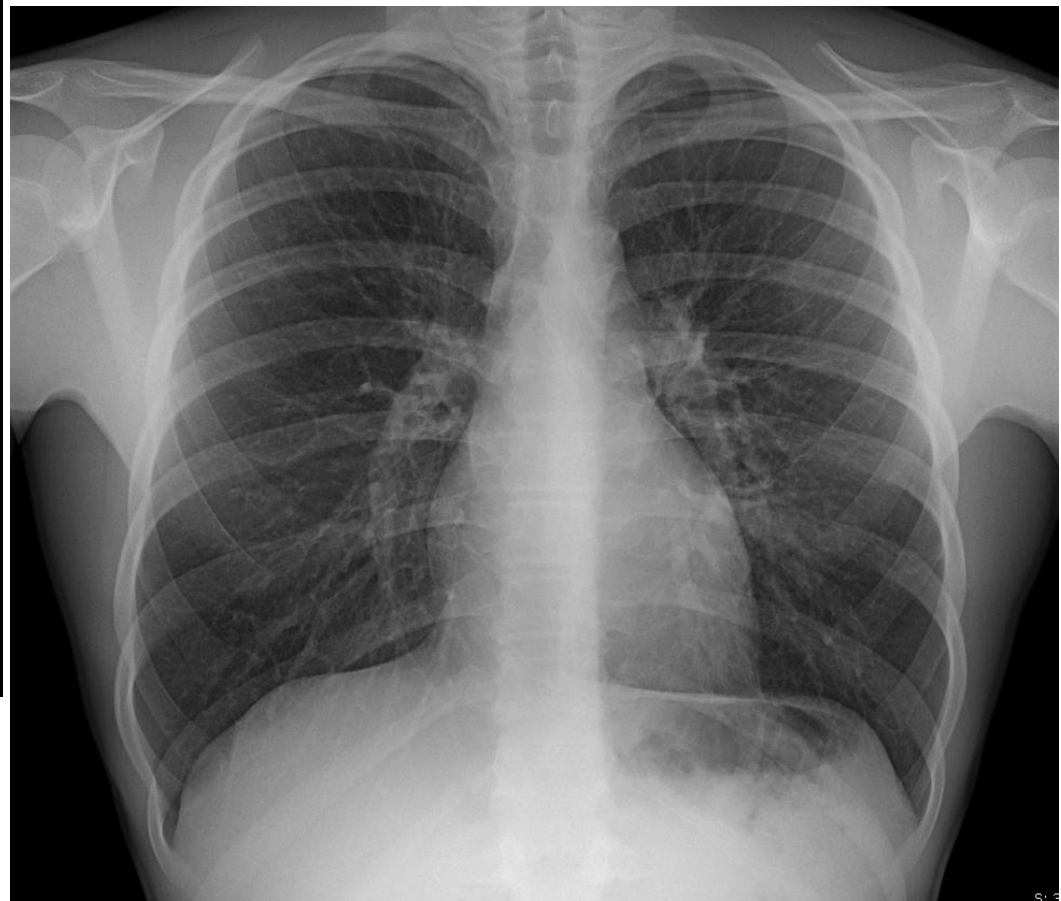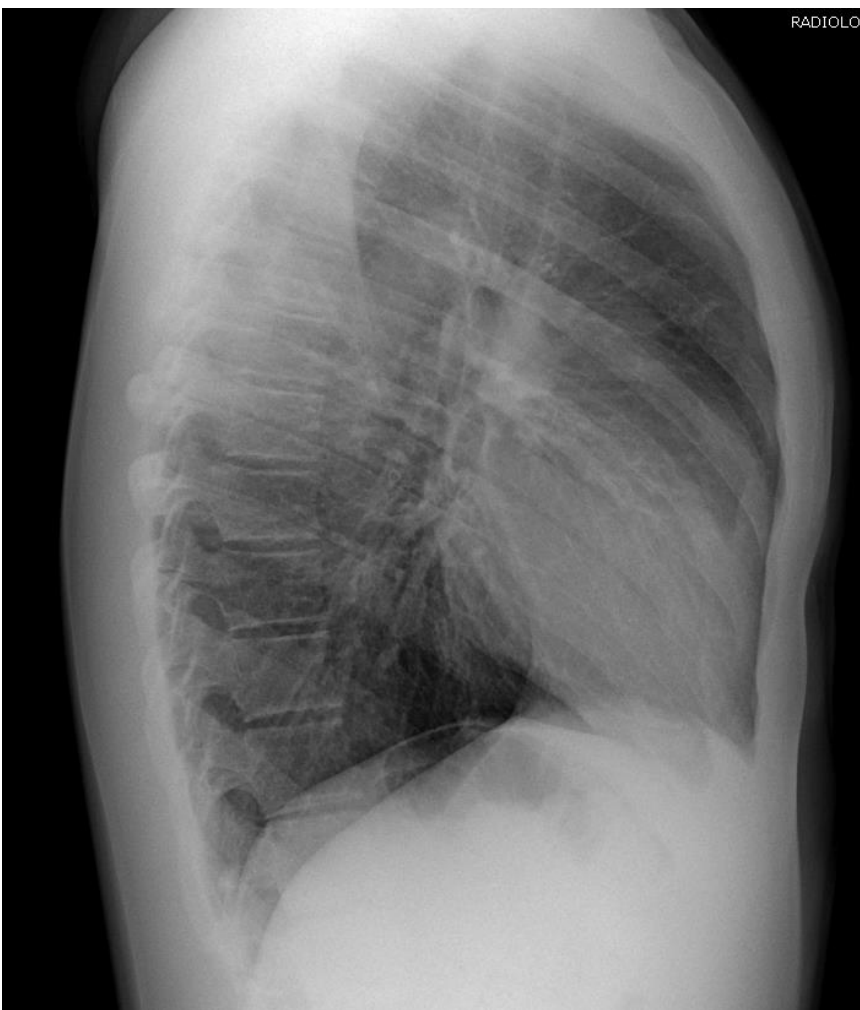**Fusion imaging**





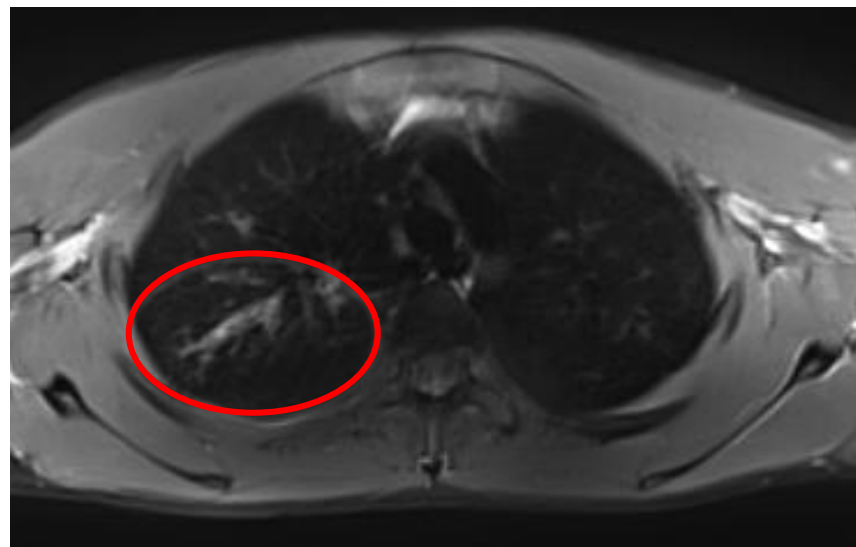
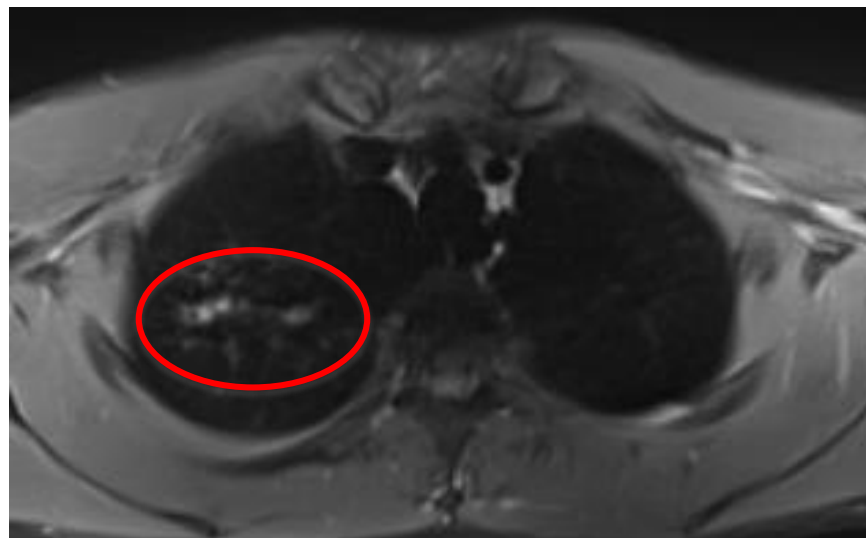
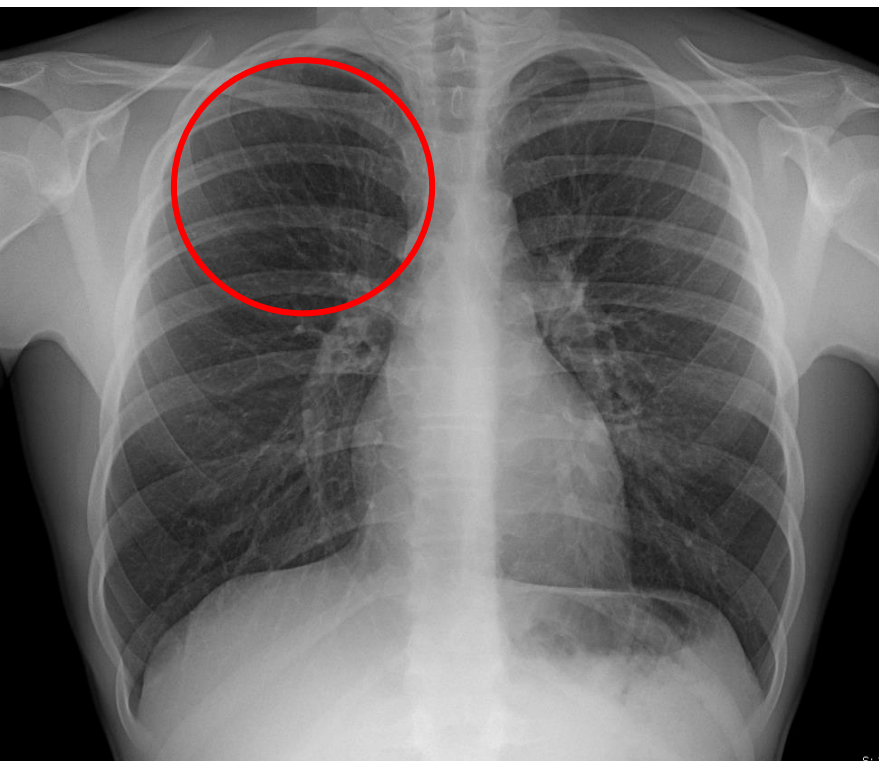


# Chest X-RAY



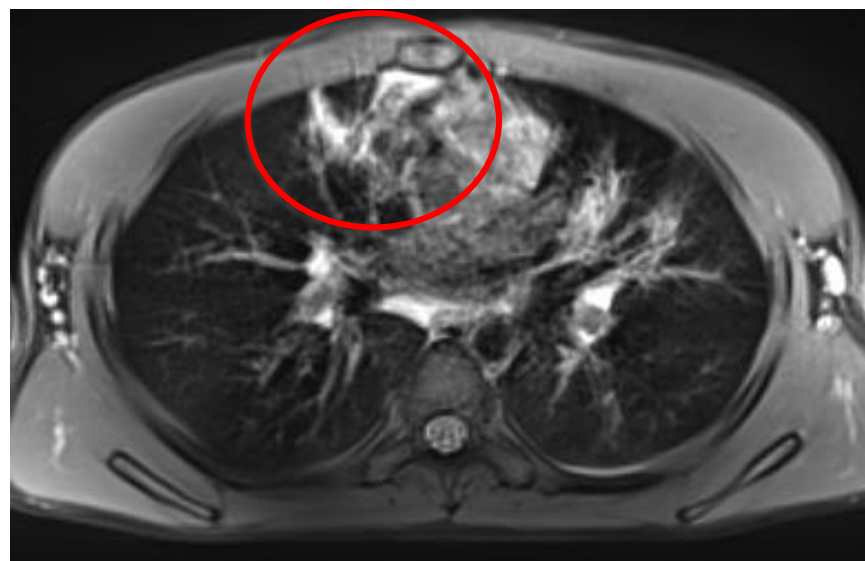
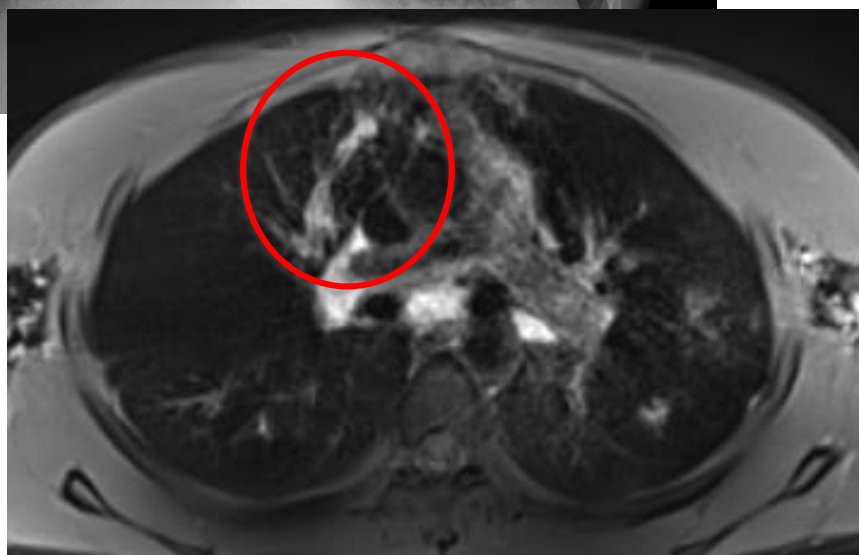
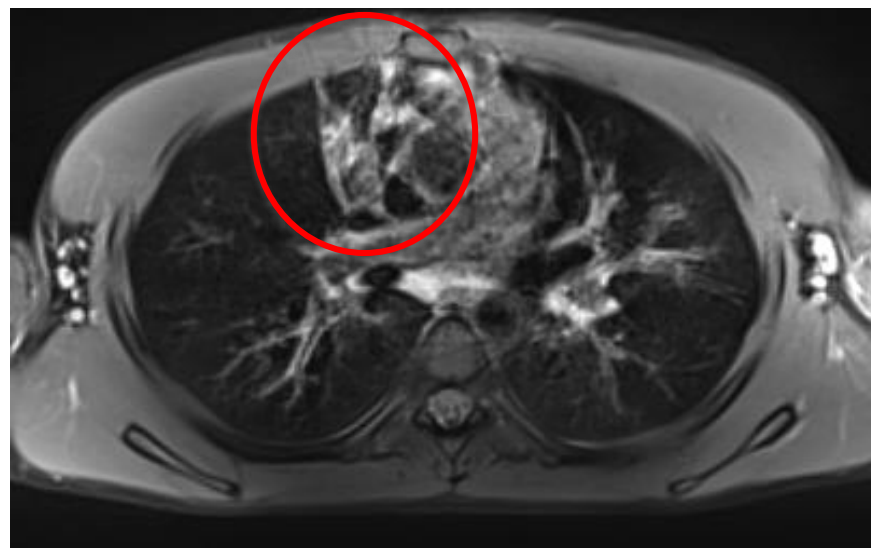
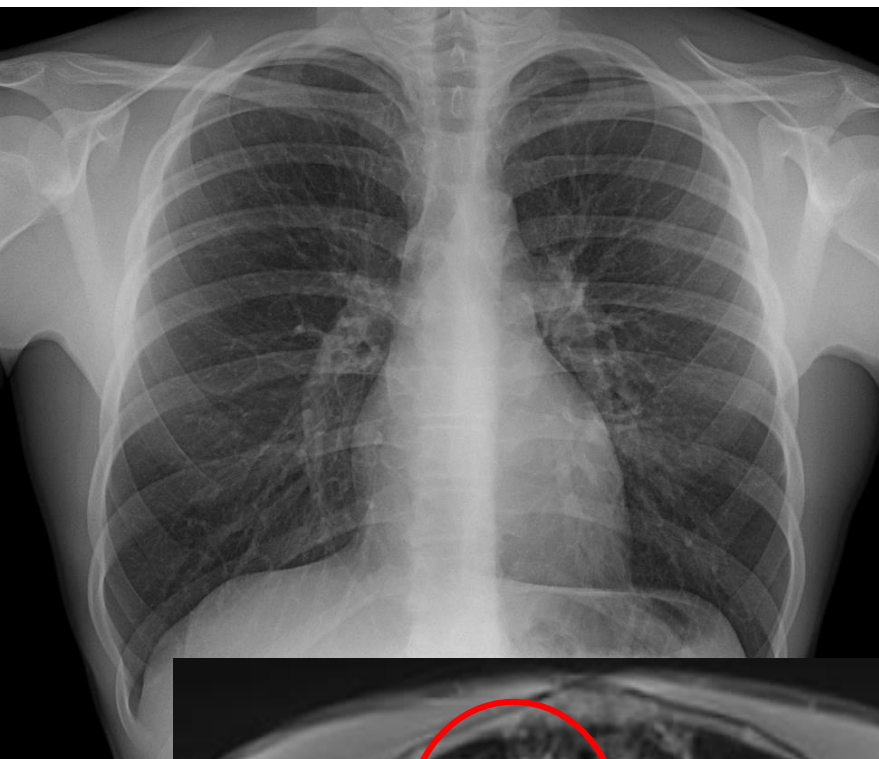


# Chest X-RAY



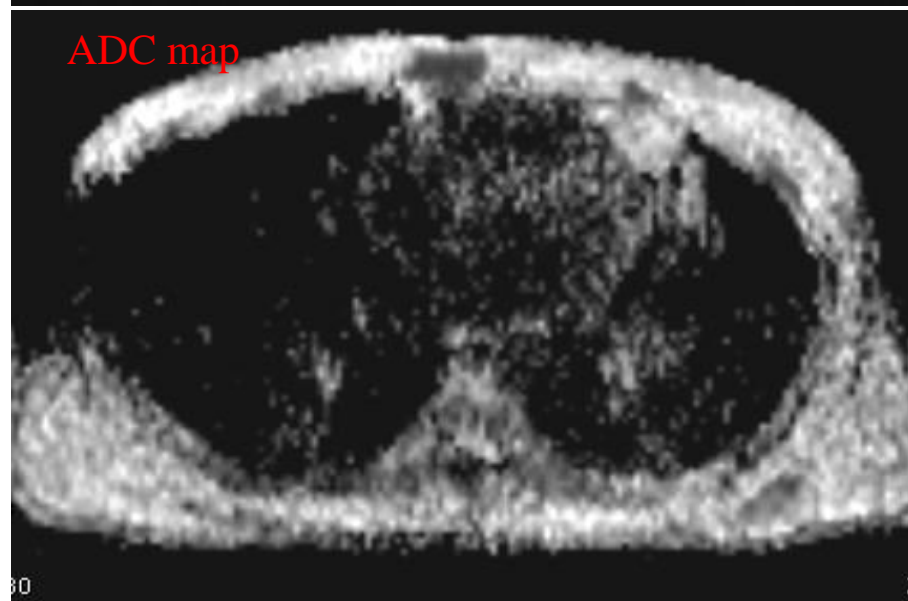
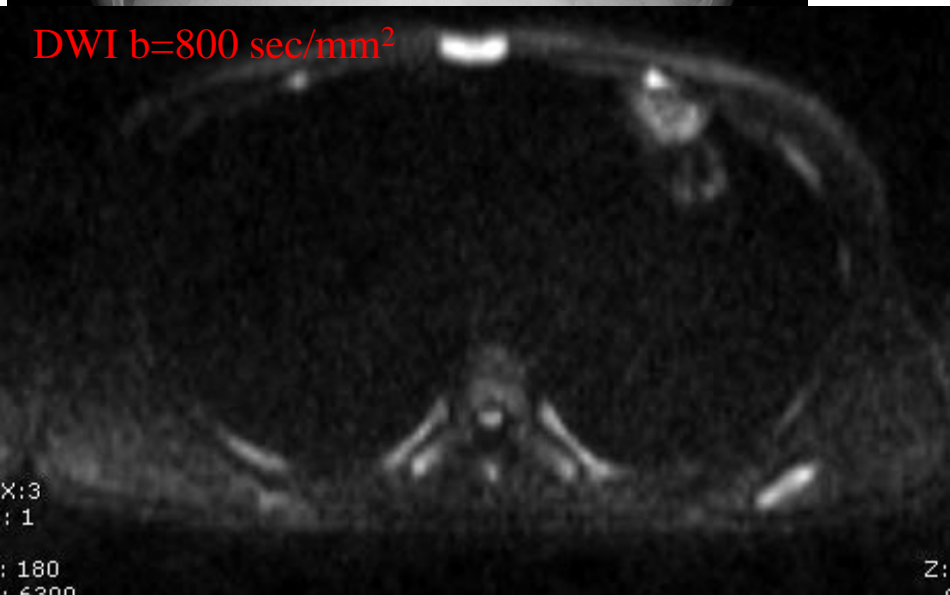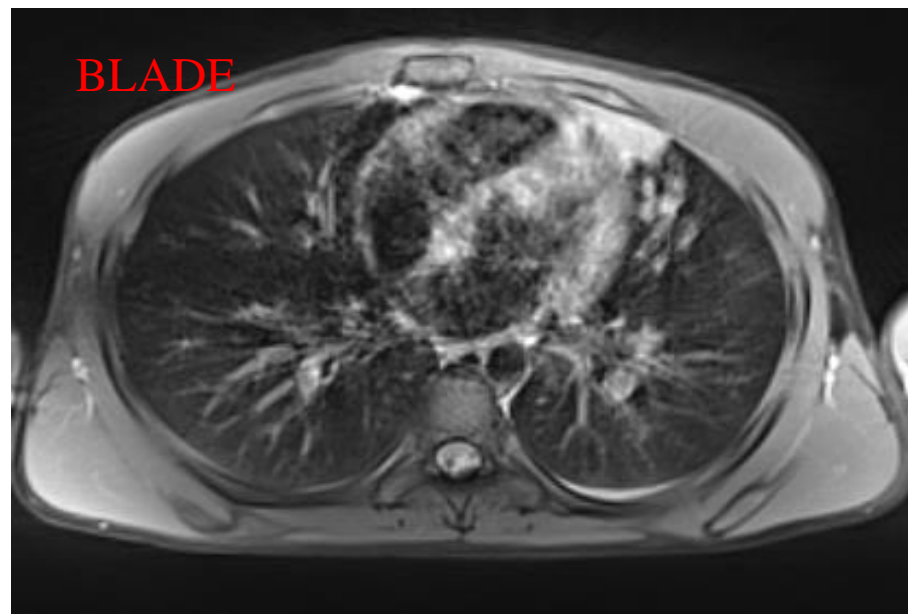
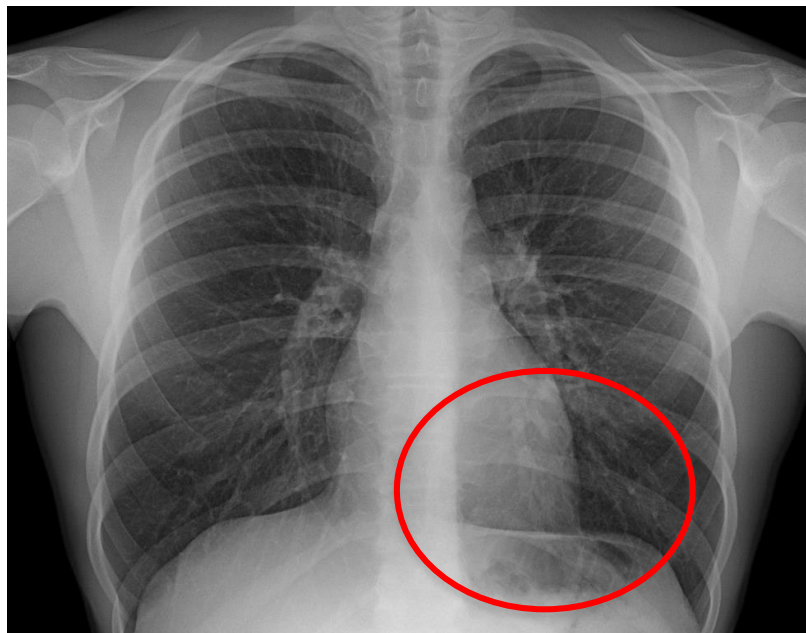


# Chest X-RAY





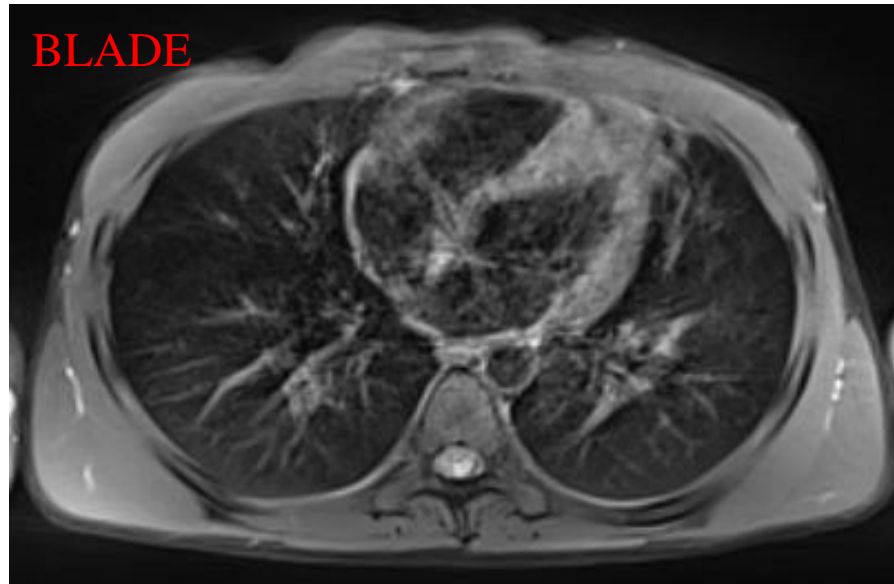
# 1° Examination before antibiotic treatment



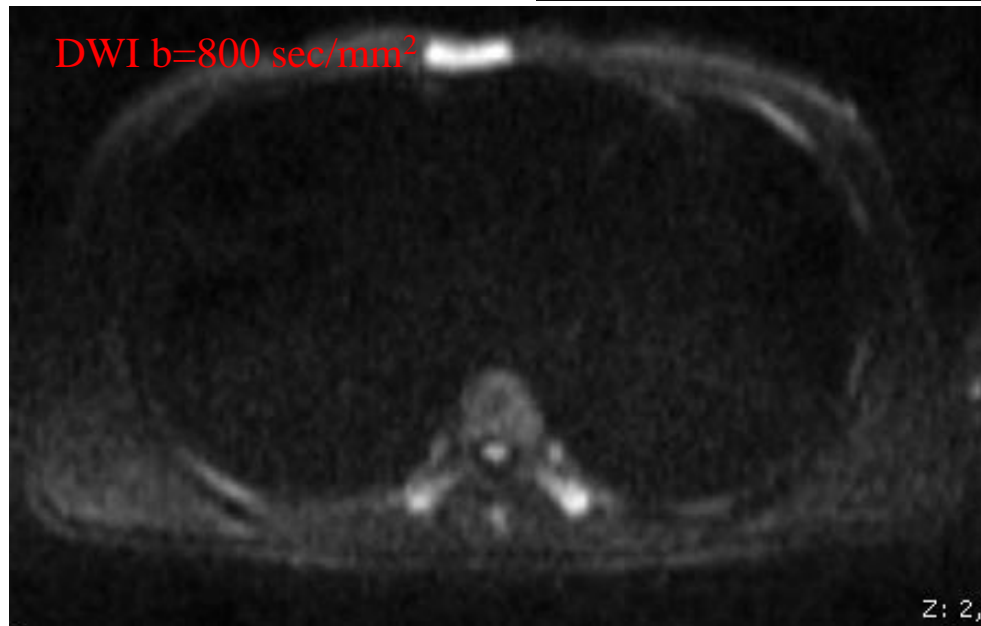


**dopo trattamento**

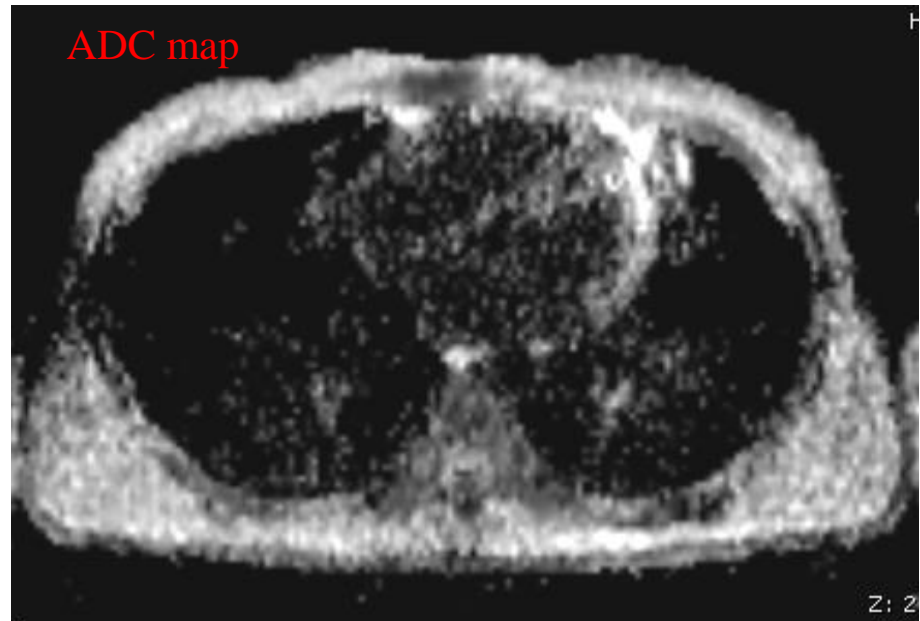
## 2° Examination after antibiotic treatment



DWI b=800 sec/mm<sup>2</sup>

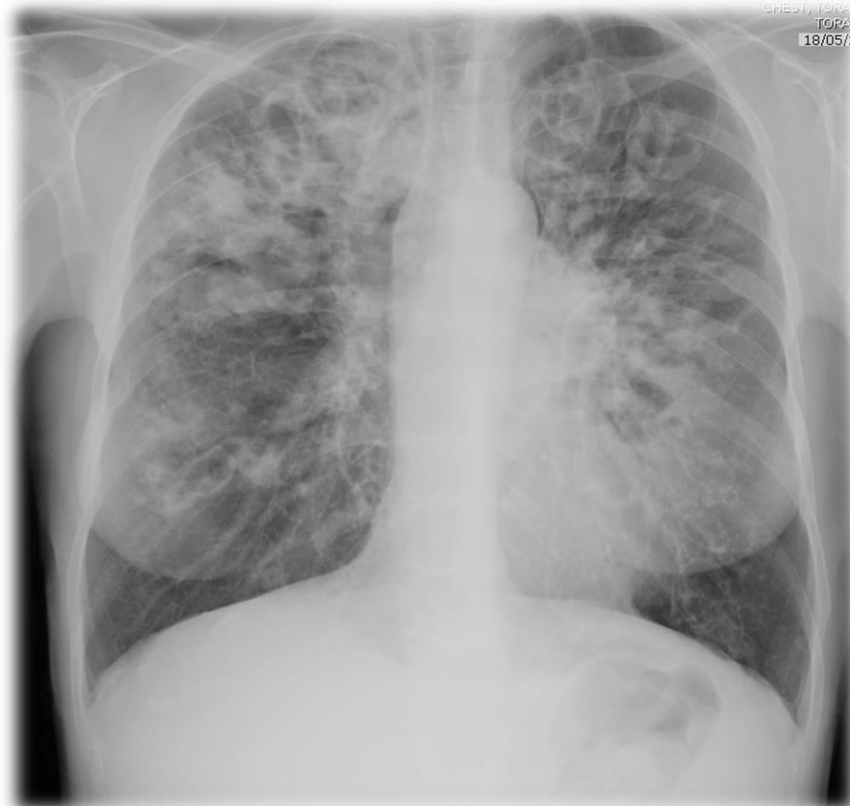
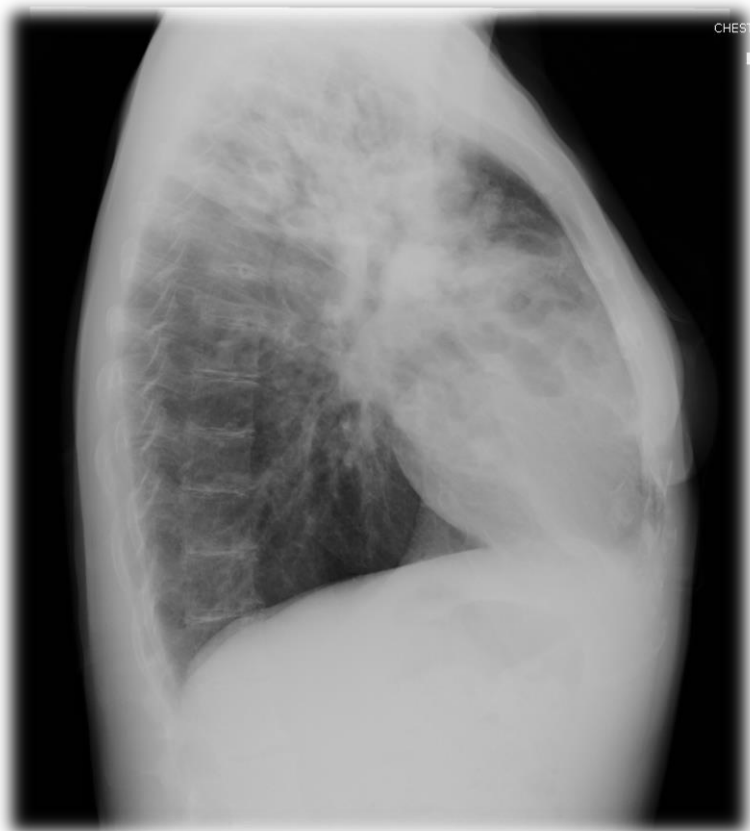
ADC map

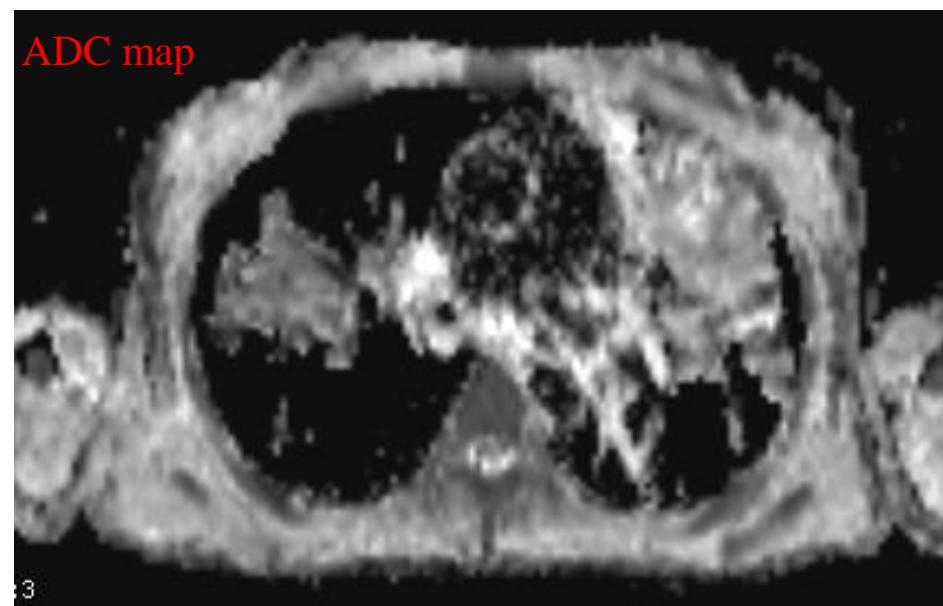
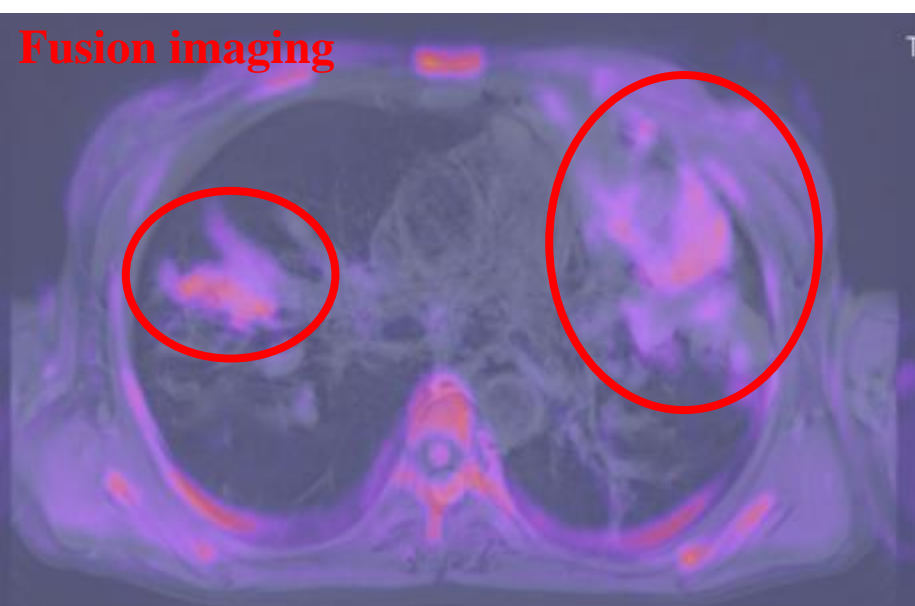
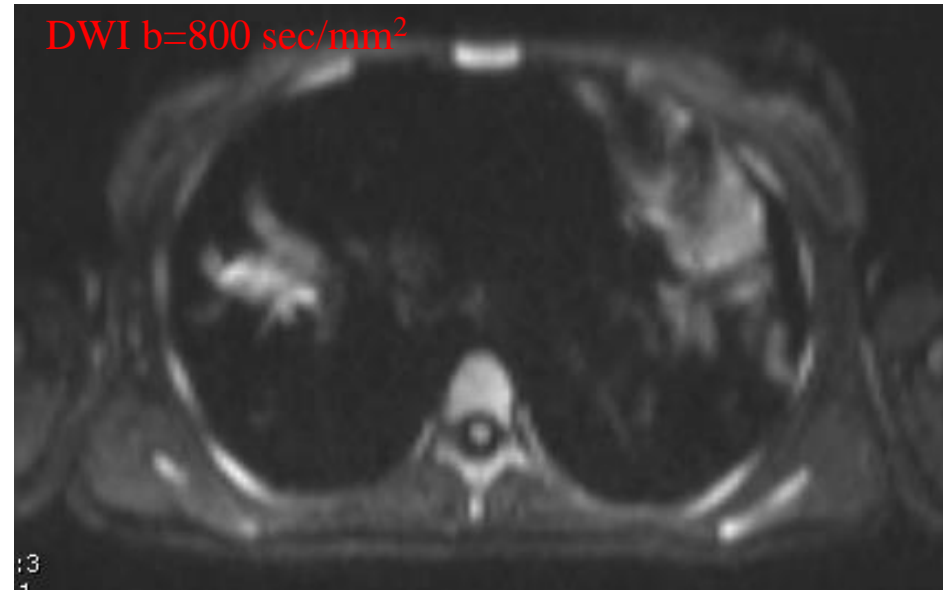
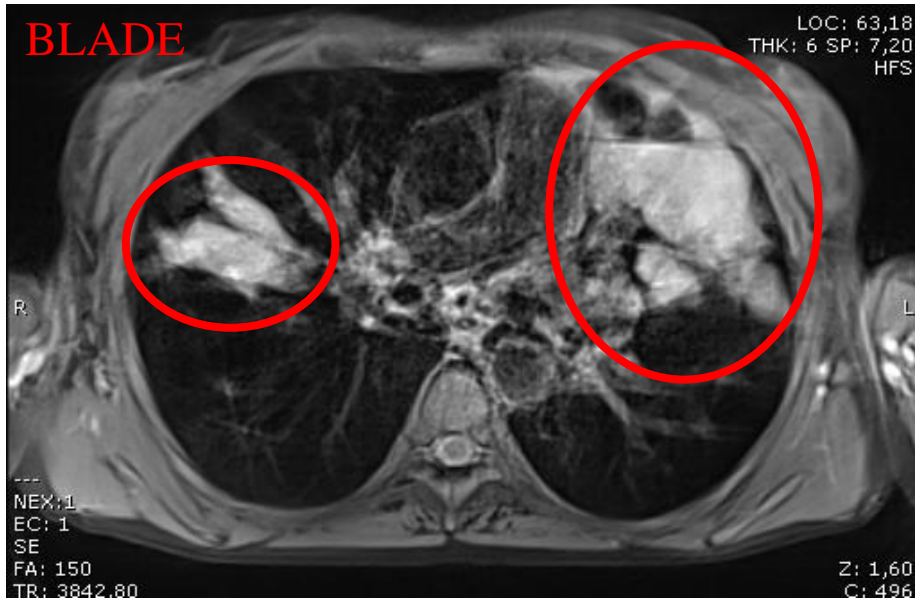




# Chest X-RAY



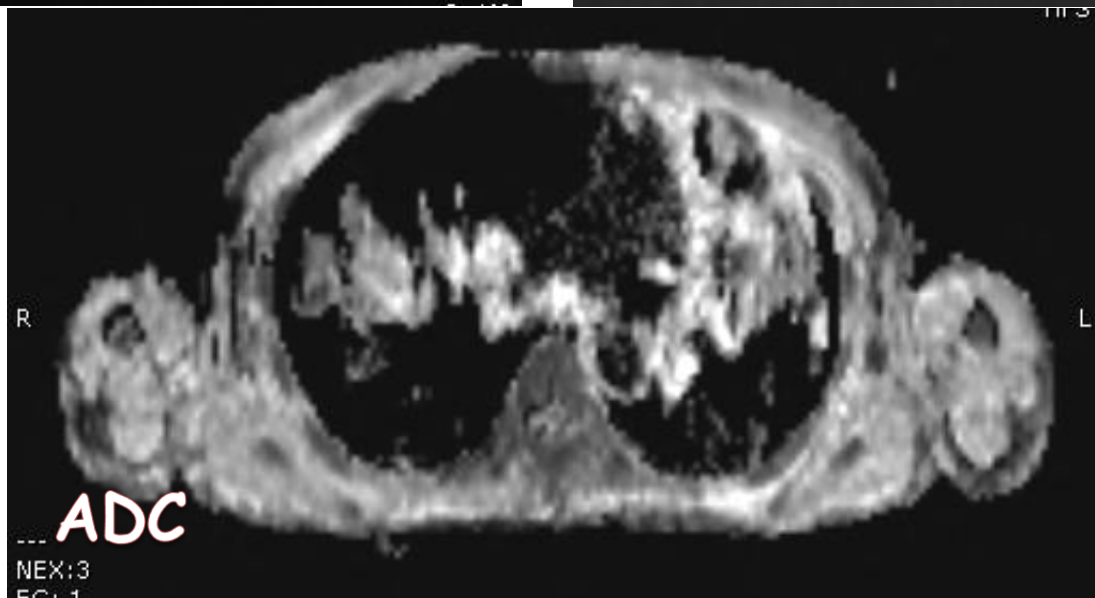
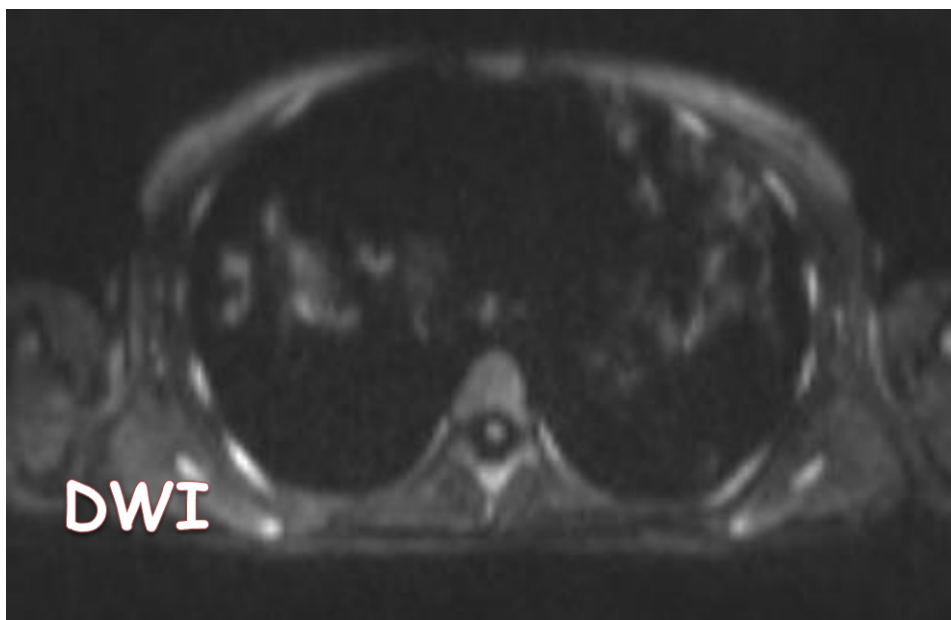
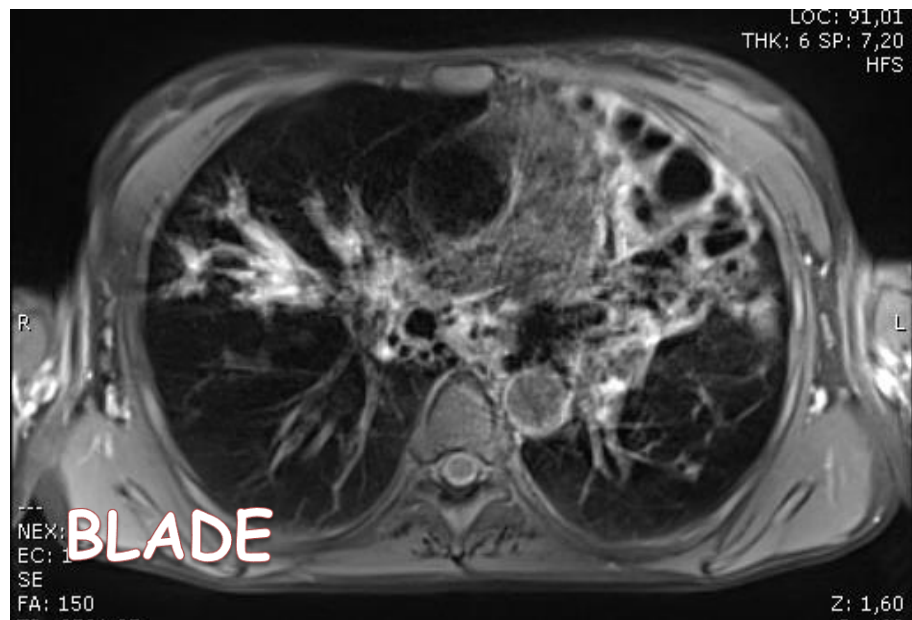
# 1° Examination before antibiotic treatment



dopo trattamento



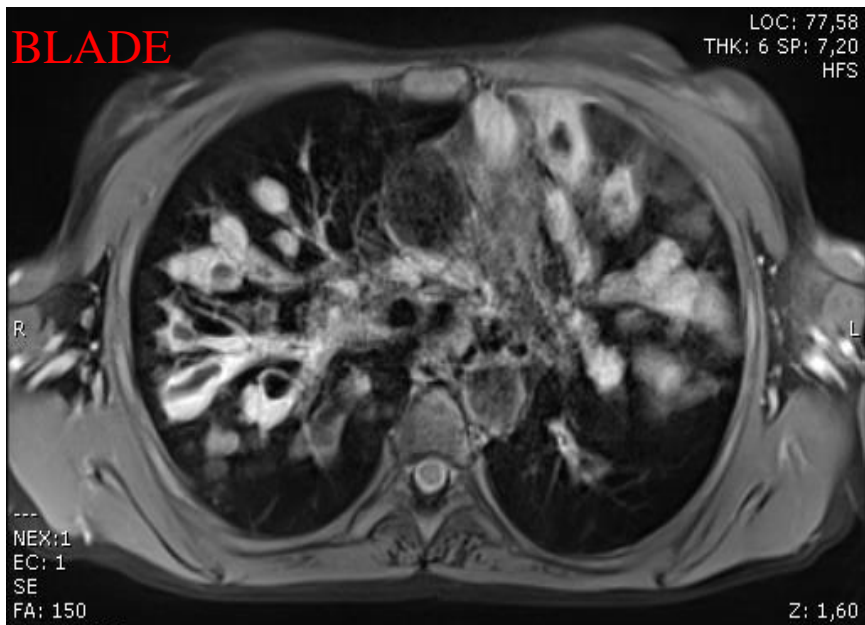# 2° Examination after antibiotic treatment (3 weeks later)



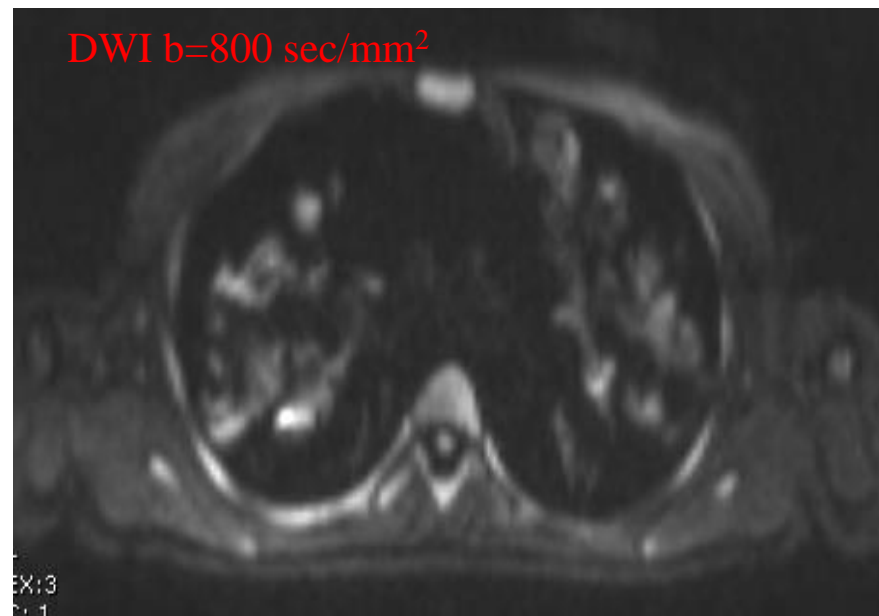


# 1° Examination before antibiotic treatment

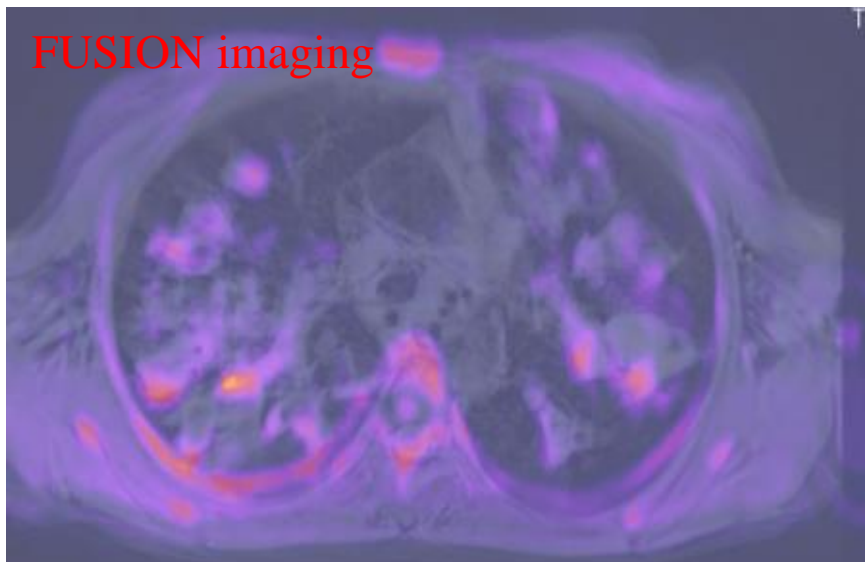
**BLADE**



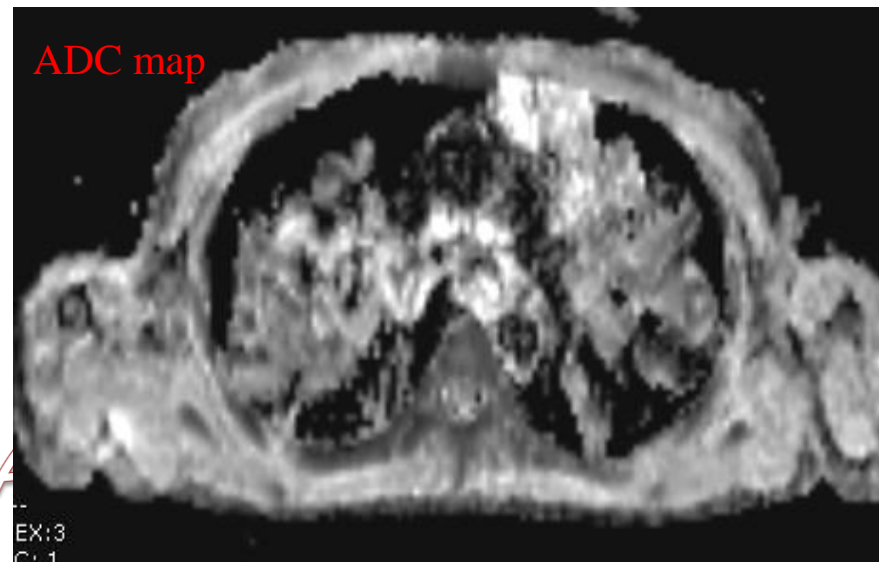
**DWI b=800 sec/mm<sup>2</sup>**



**FUSION imaging**



**ADC map**

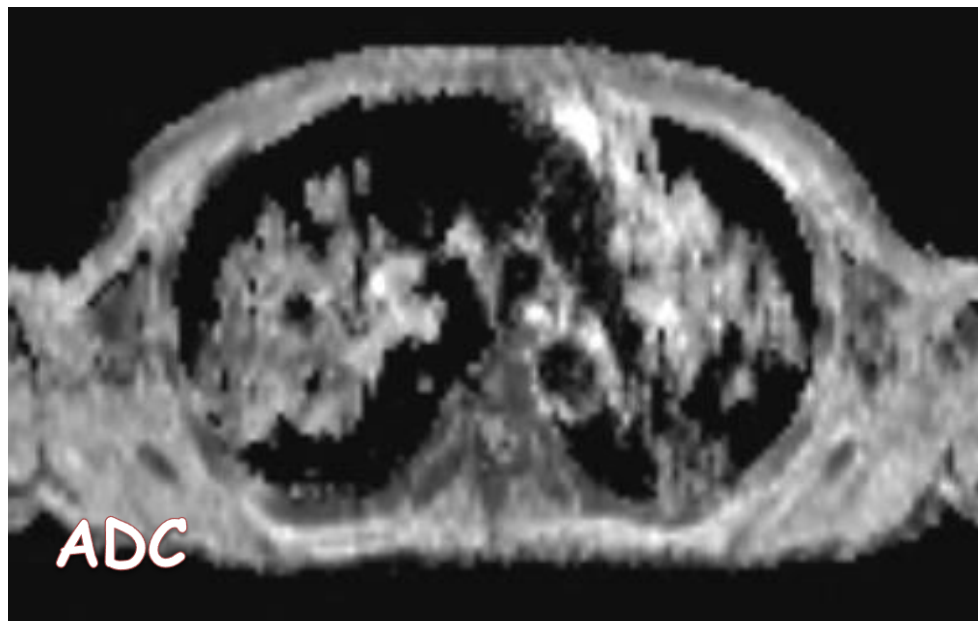
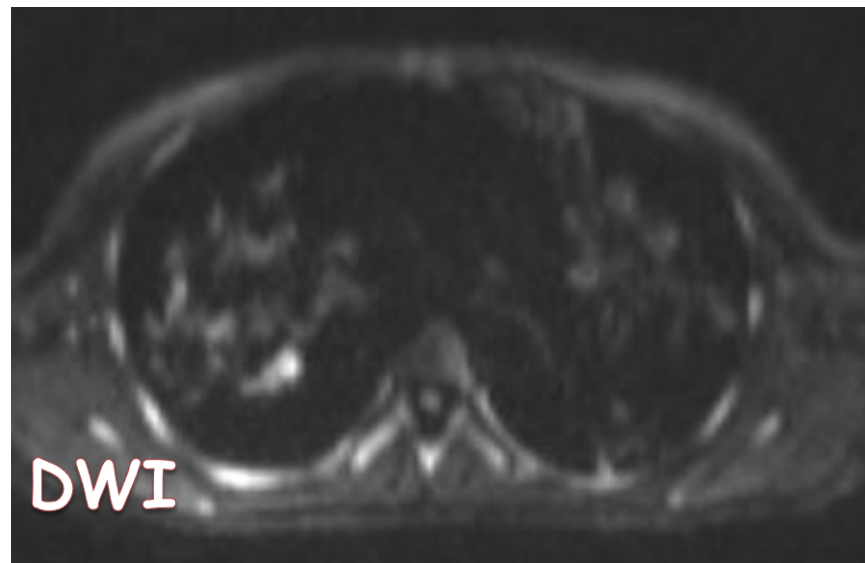
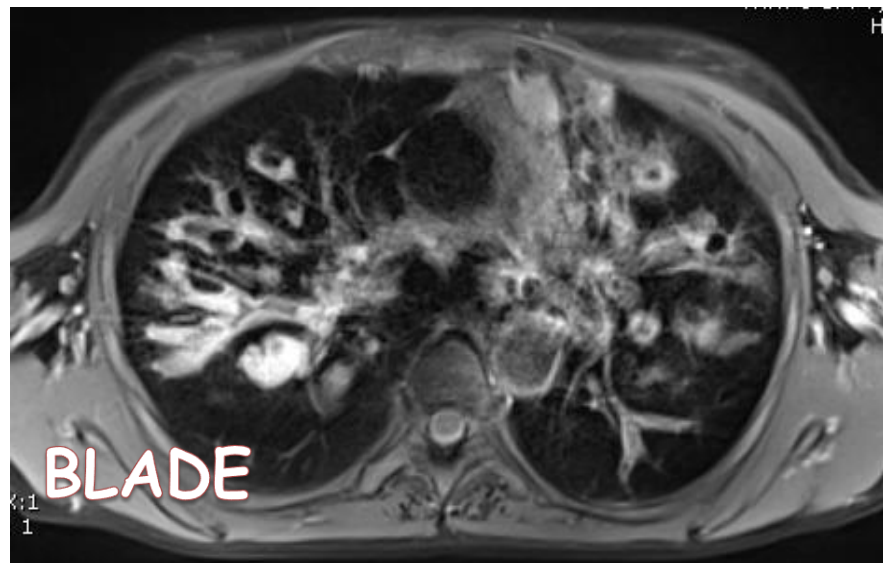


dopo trattamento





# 2° Examination after antibiotic treatment (3 weeks later)





# ...nuove frontiere RM

Paziente con esacerbazione acuta:

RM (DWI) PRIMA e DOPO terapia



Valutazione

- zone flogistiche
- impatti di muco



strategia terapeutica

# RX vs RM

Esperienza Treviso 2011-2012



Numero RX e RM "invertito"



$$RM \times 3 - RX \quad 12$$

# RM perfusione

## A. Distribuzione del flusso arterioso polmonare

individua zone dove la vascolarizzazione è alterata (ridotta/tardiva) per fenomeni di vasocostrizione ipossica con successiva omogeneizzazione per:

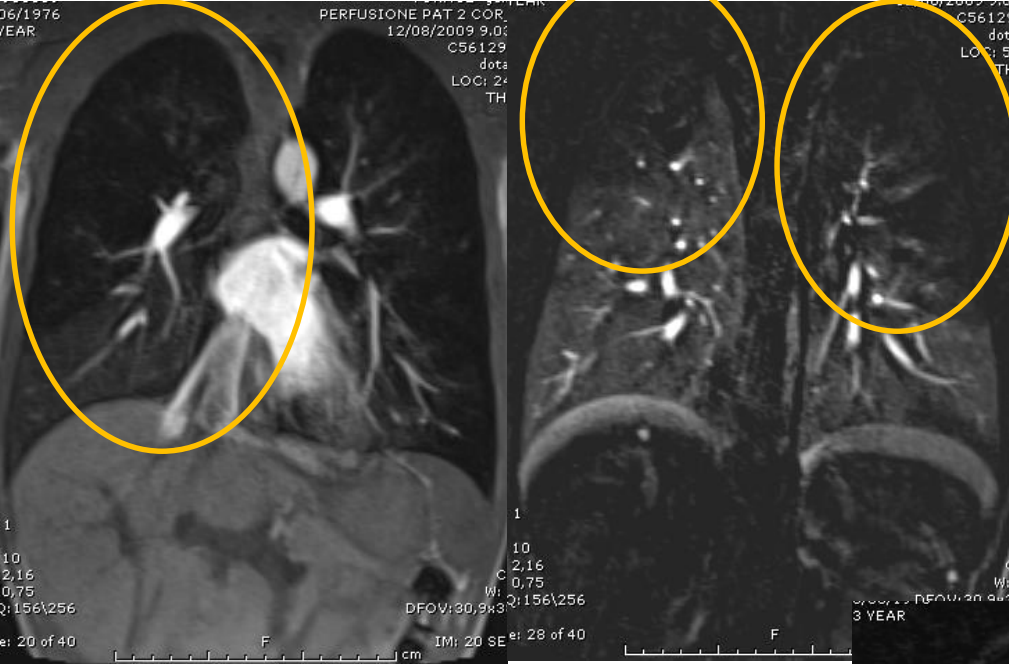
- semplice ritardo di perfusione
- azione vicariante da arteria bronchiale ipertrofica

## B. Presenza di ipertrofia delle arterie bronchiali

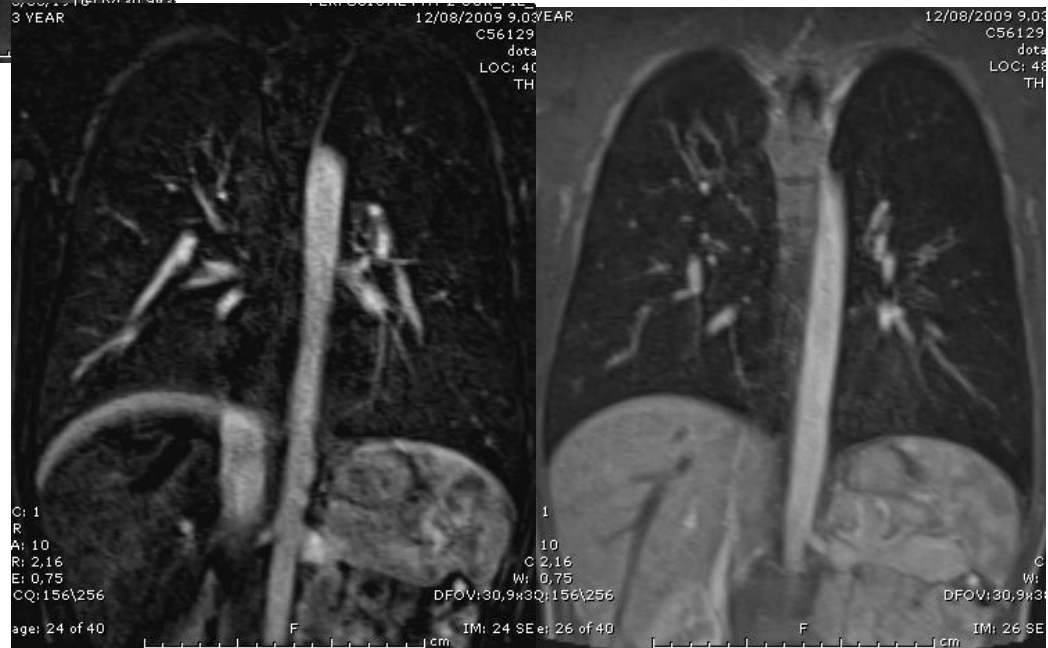
fenomeno di compenso in zone dove la vascolarizzazione arteriosa polmonare è alterata

# 1. RITARDO DI PERFUSIONE

Vascularizzazione polmonare tardiva  
per vasocostrizione ipossica

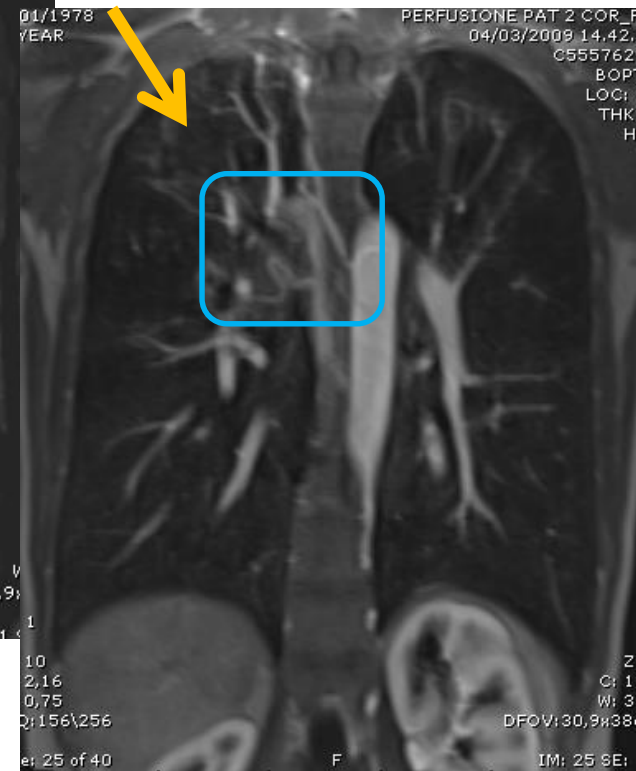
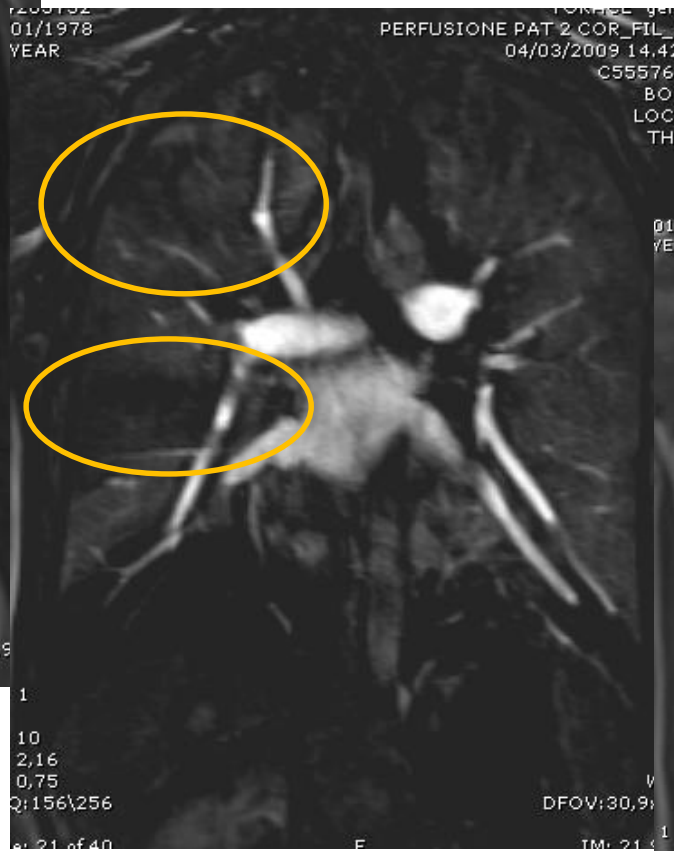
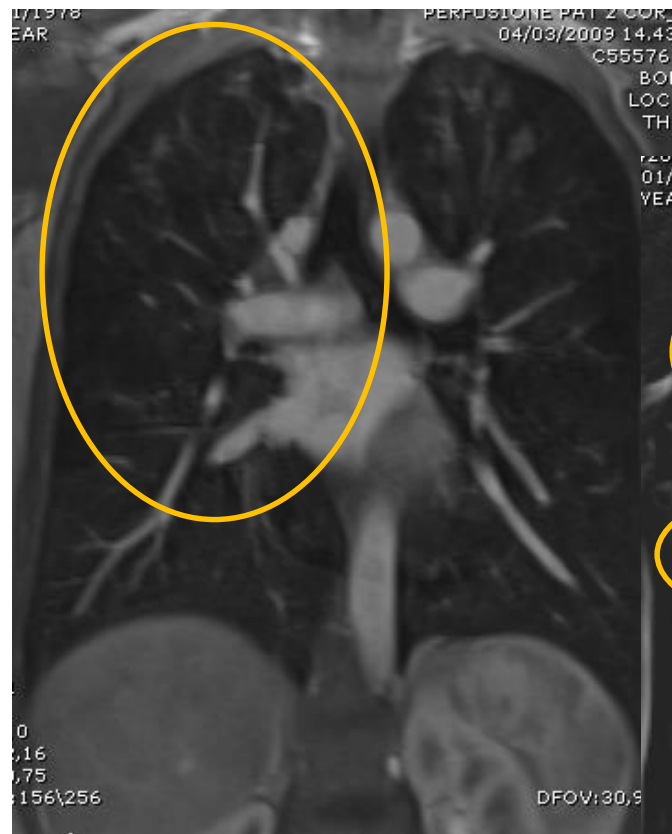
omogeneità perfusionale tardiva,  
senza ipertrofia arteria  
bronchiale

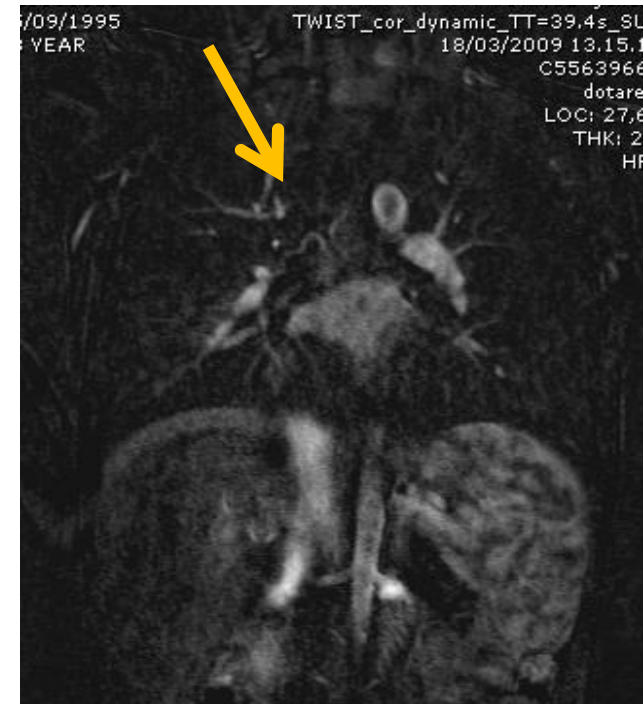
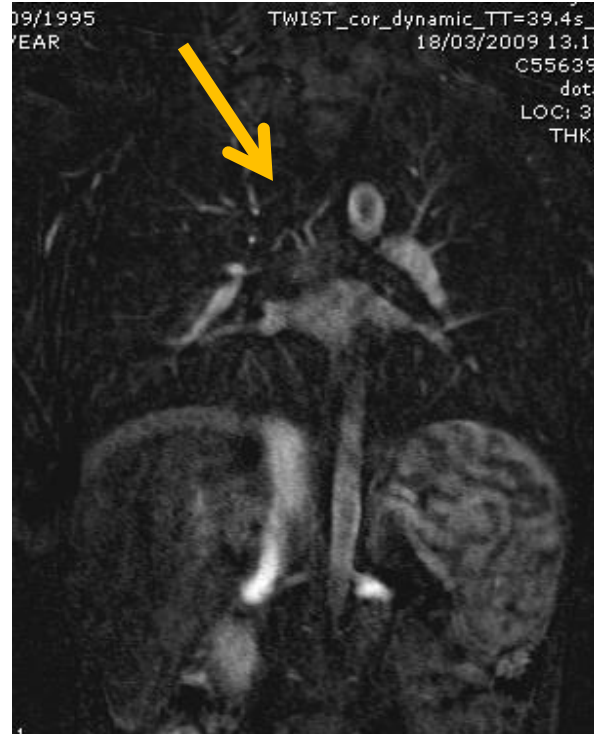
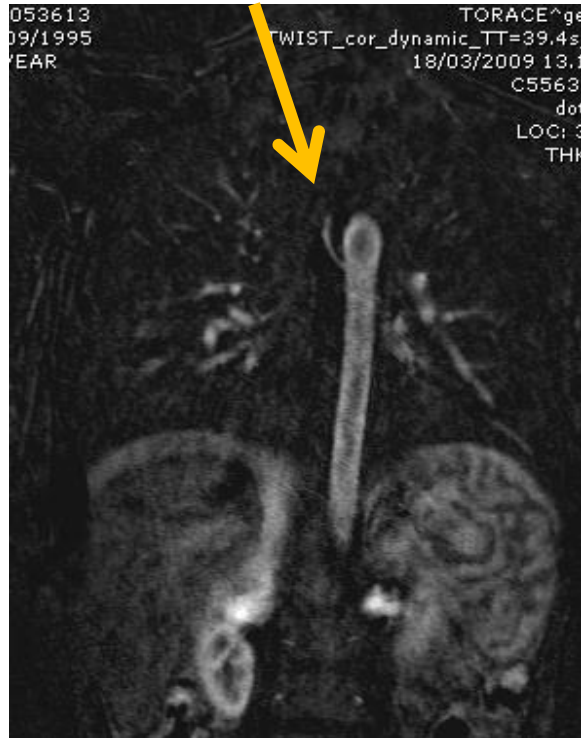# 2. PERFUSIONE SISTEMICA

Alterata perfusione con presenza di  
arteria bronchiale ipertrofica



# ARTERIA BRONCHIALE IPERTROFICA



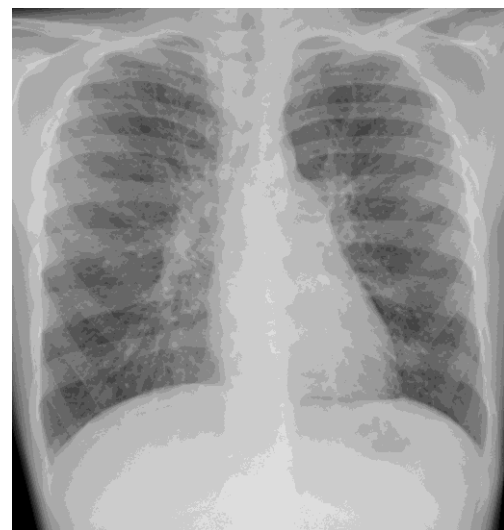
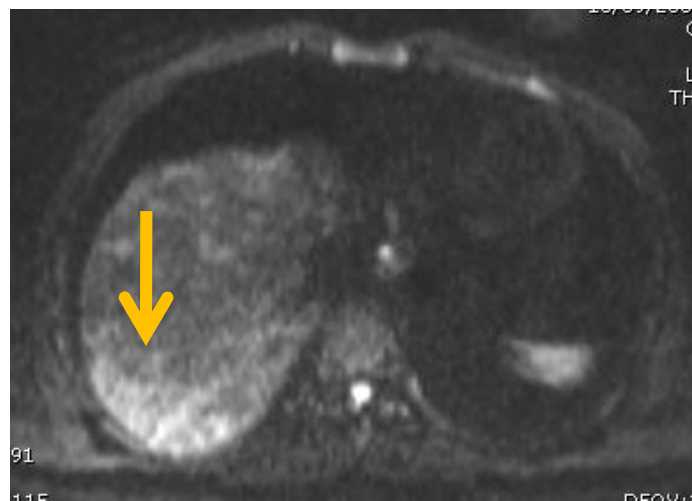
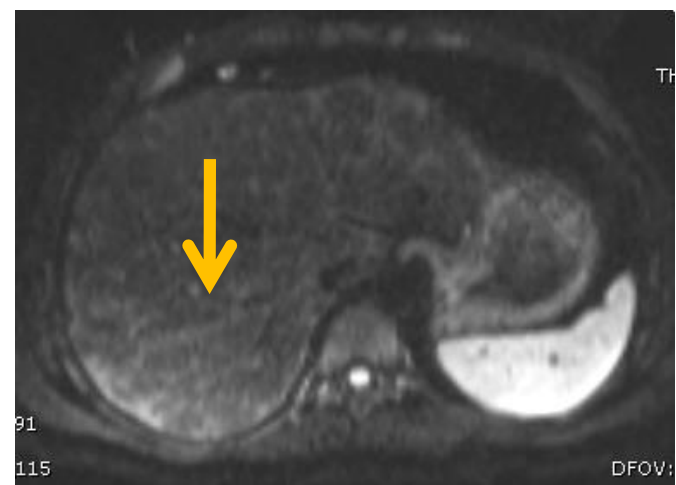
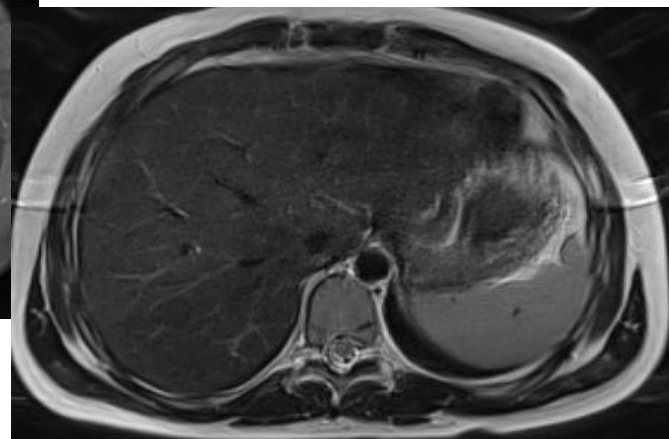
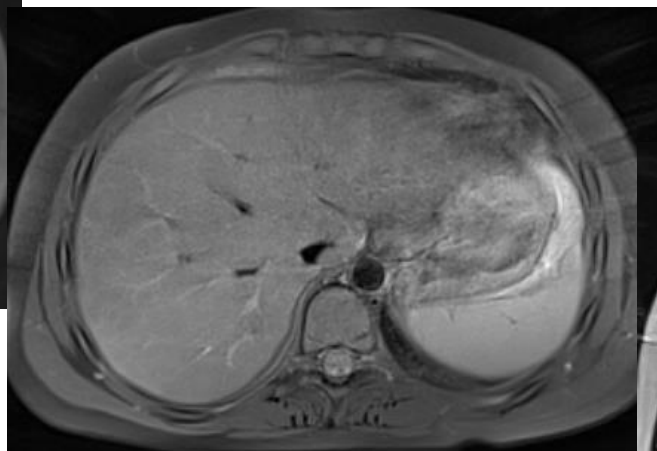
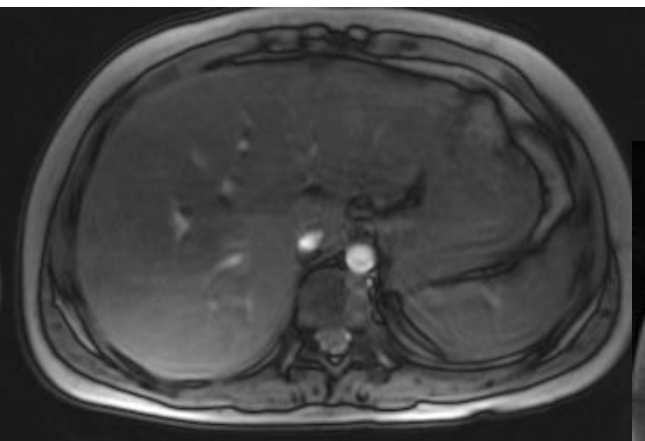
# STUDIO RM DEDICATO DEL FEGATO

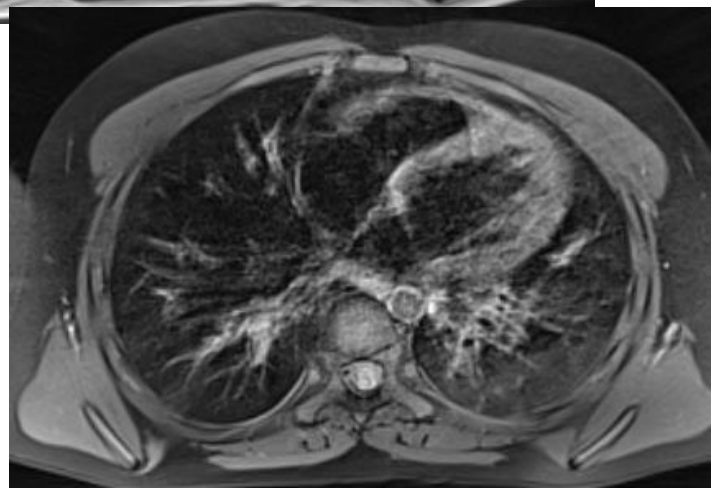
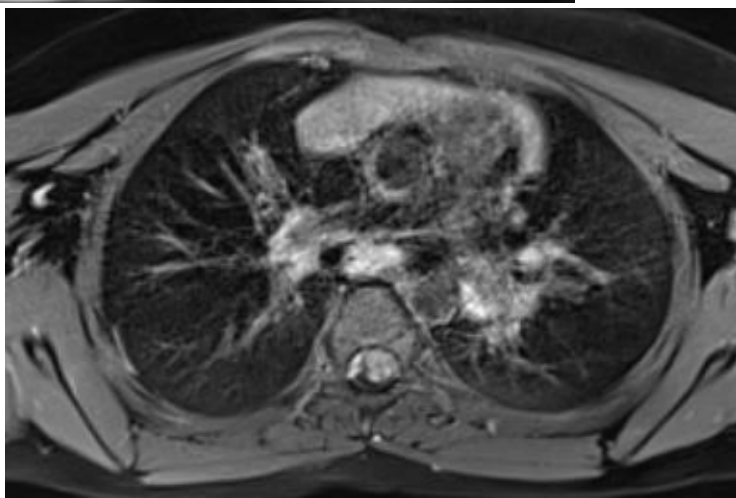
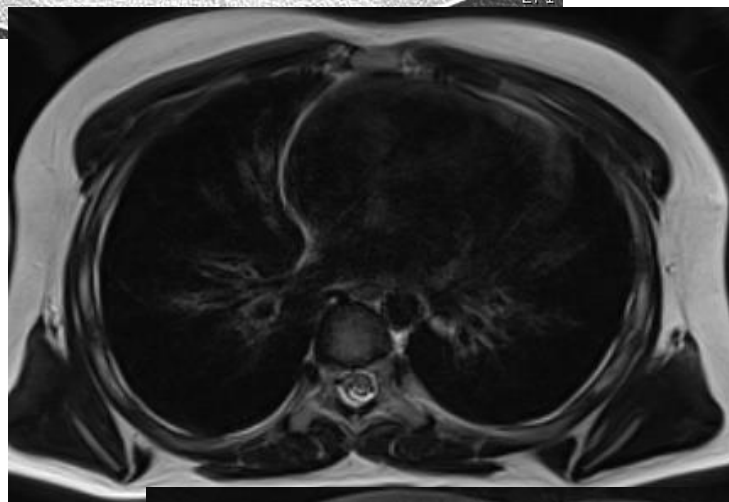
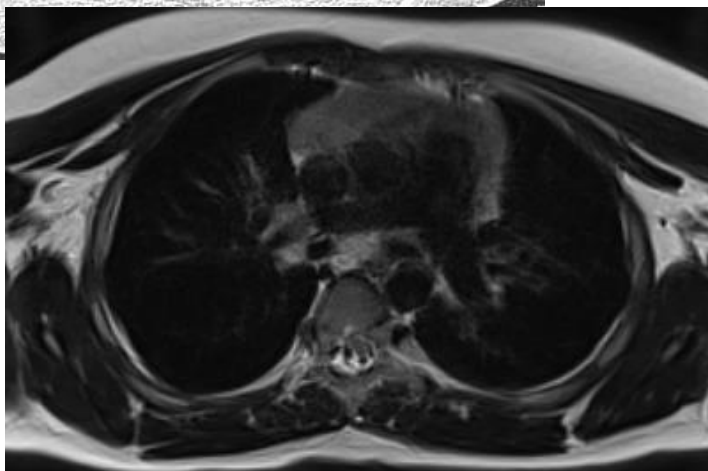
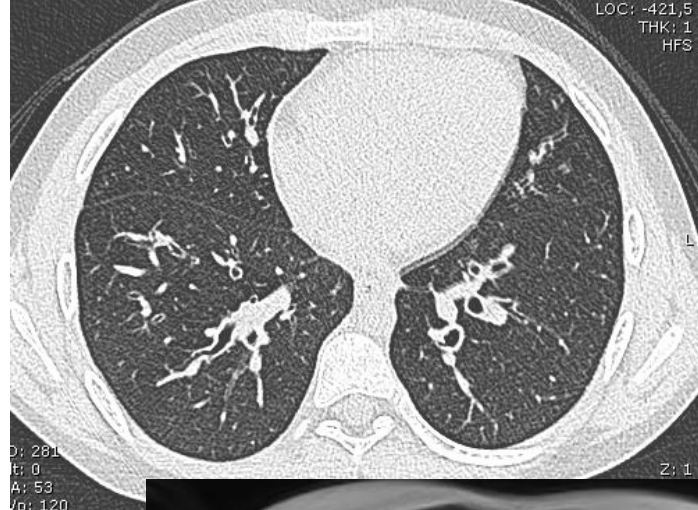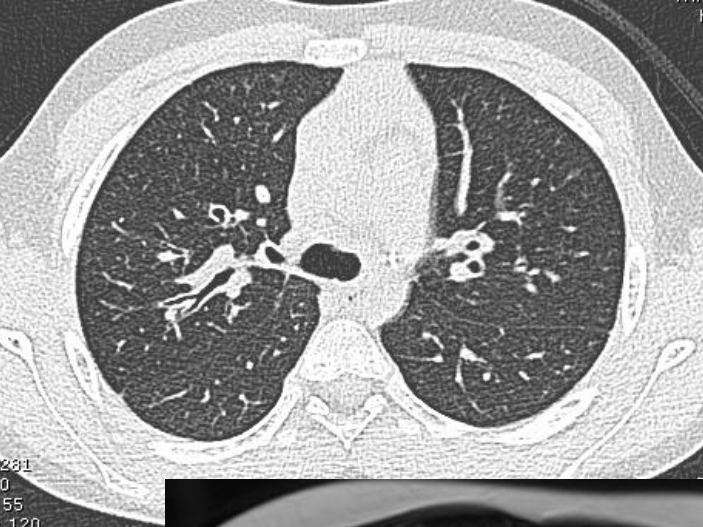
Nella stessa seduta della RM TORACE

**Diagnosi precoce di alterazioni parenchimali epatiche**



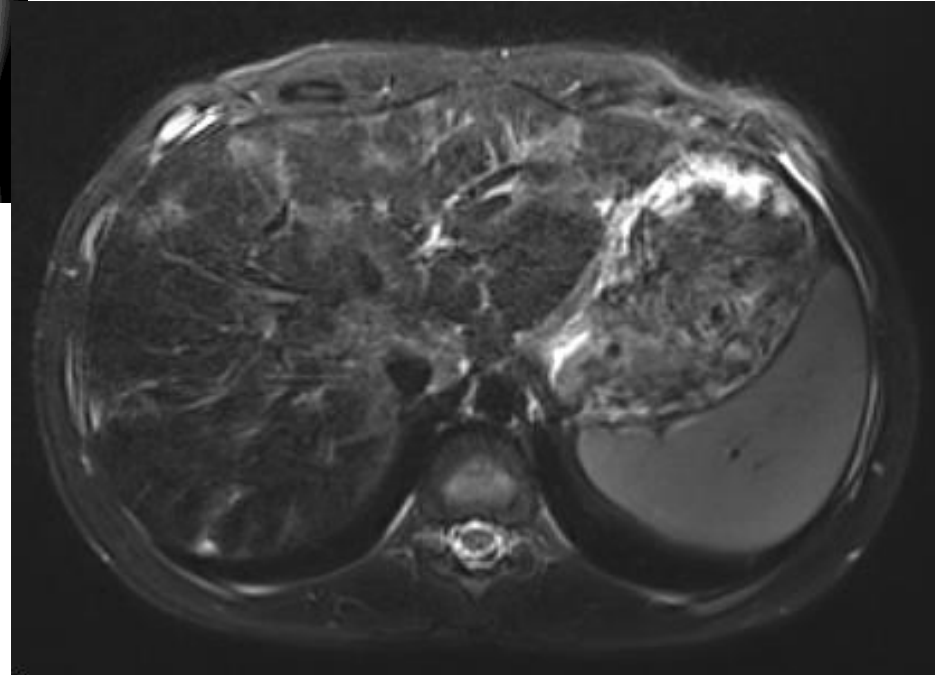
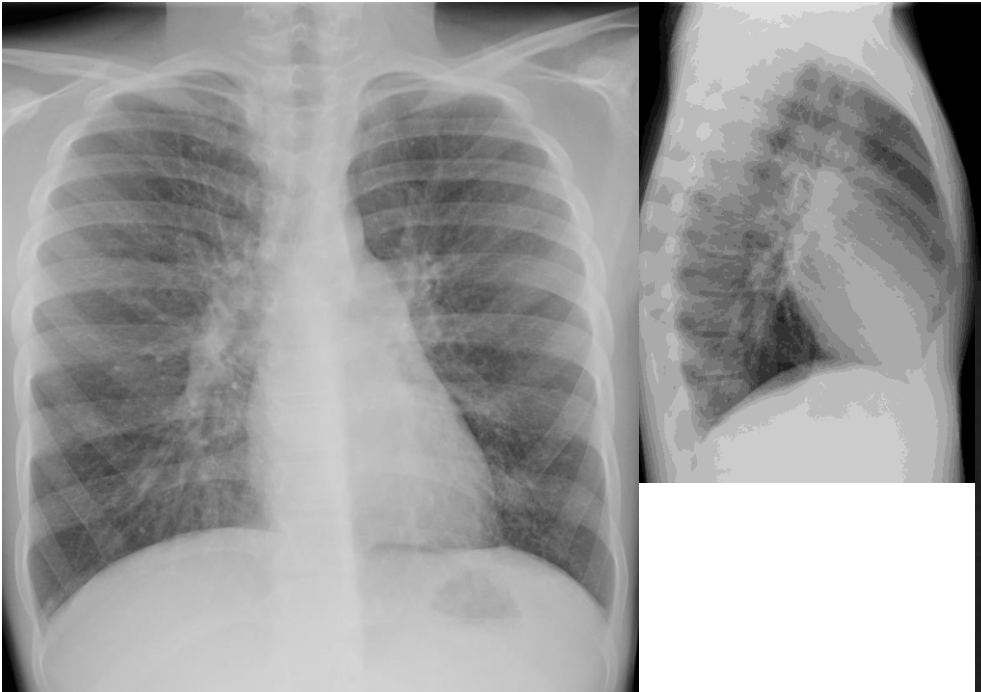13 aa

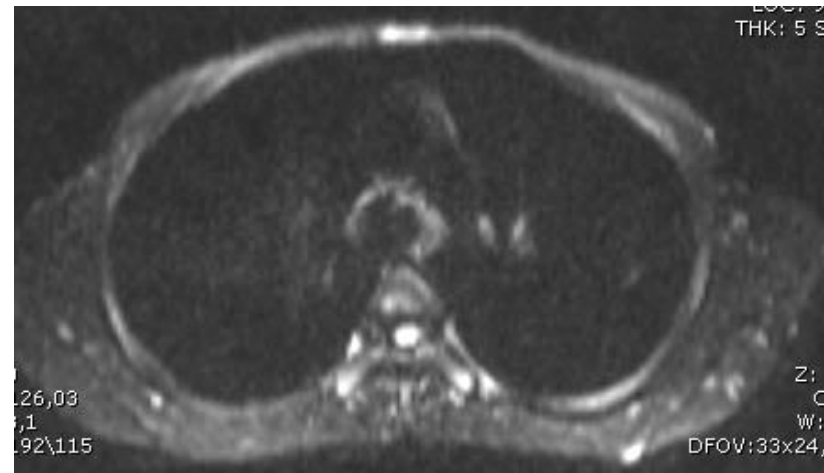
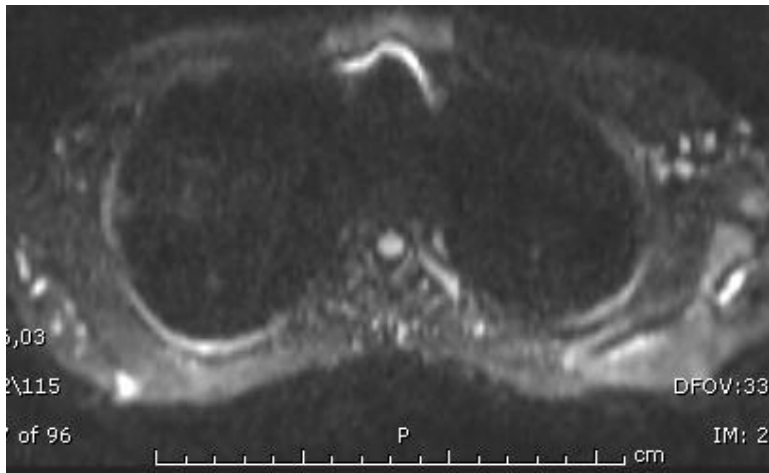
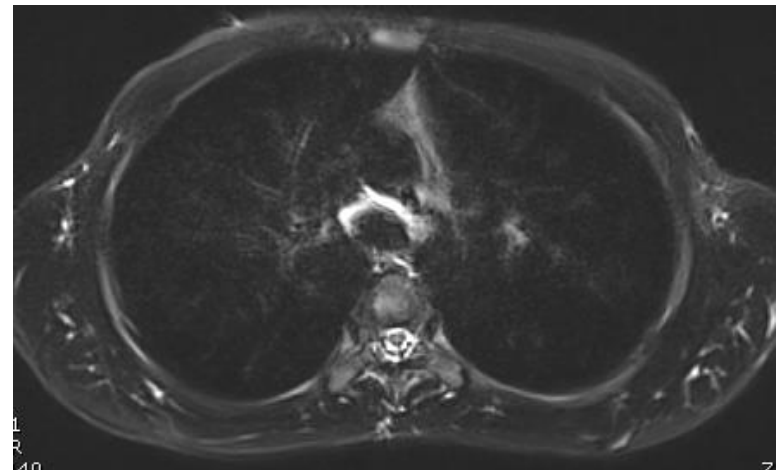
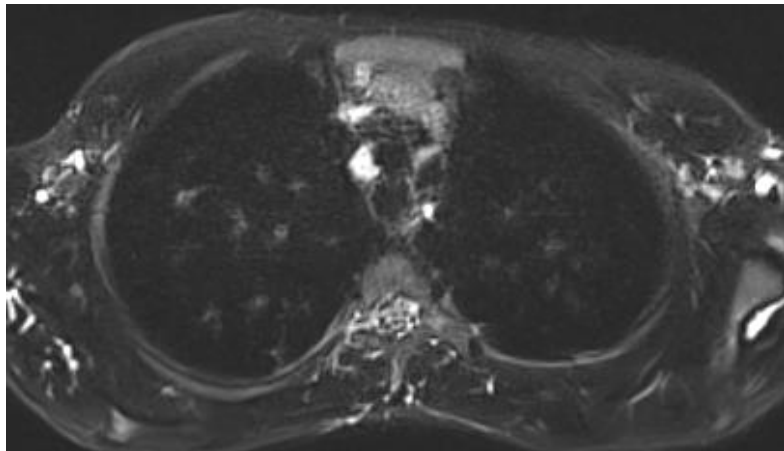
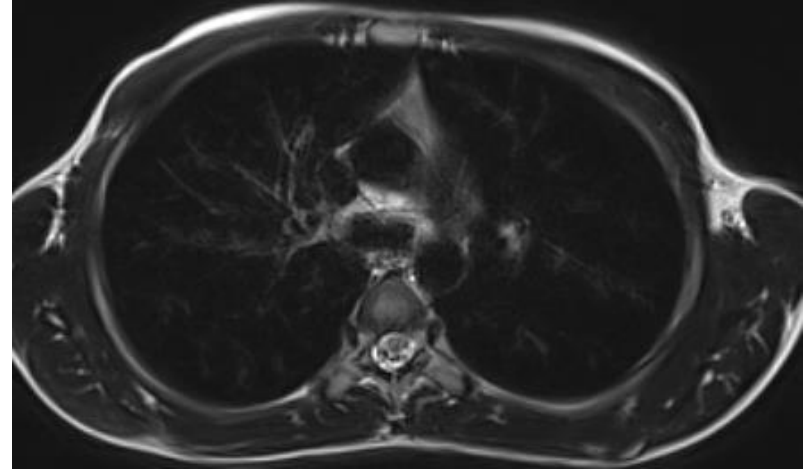
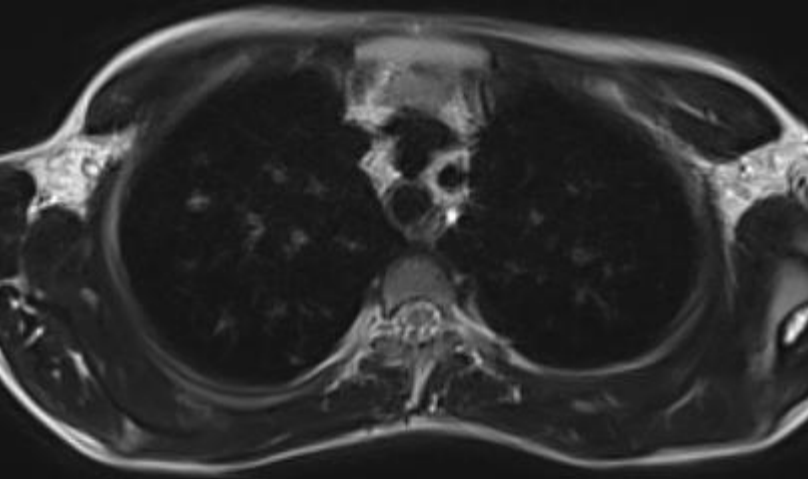




**TORACE: lievi alterazioni morfologiche polmonari**

**FEGATO: importanti alterazioni parenchimali epatiche in epatopatia fibrotica/cirrotica**





ECG: 7  
THK: 5 S

5,03  
X115  
of 96

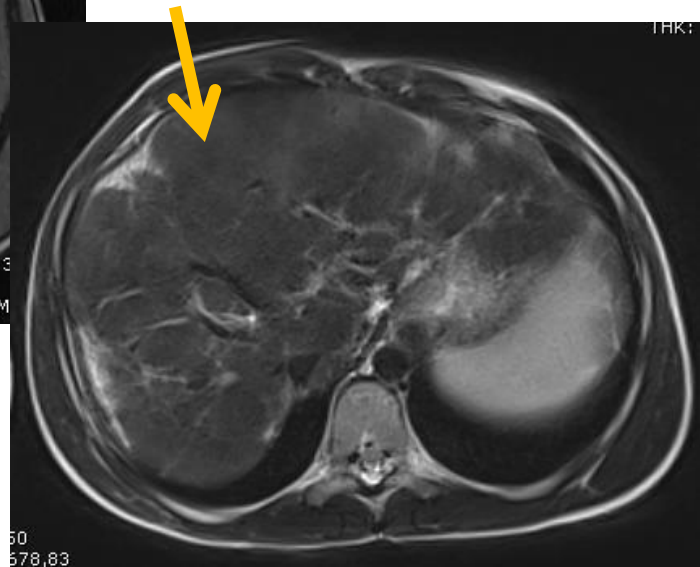
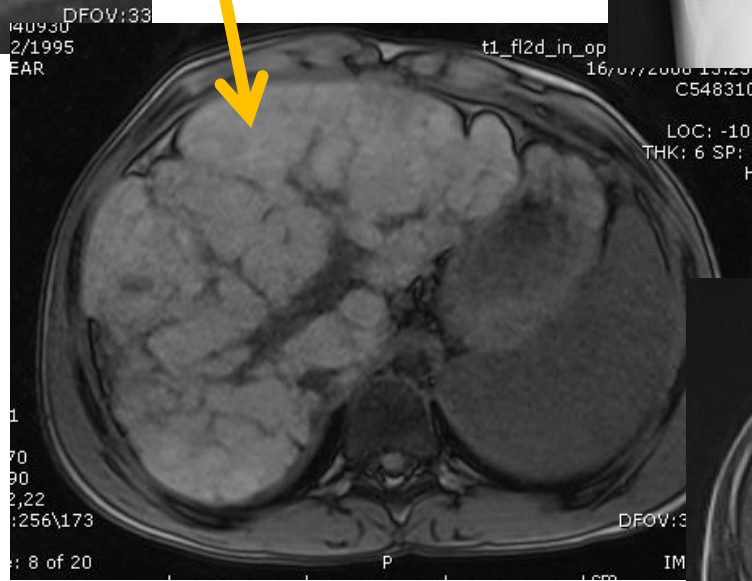
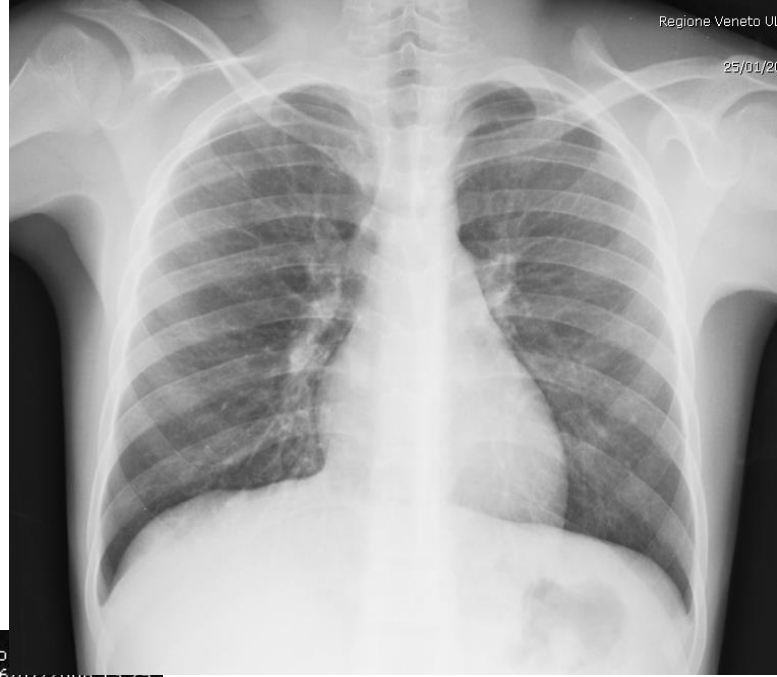
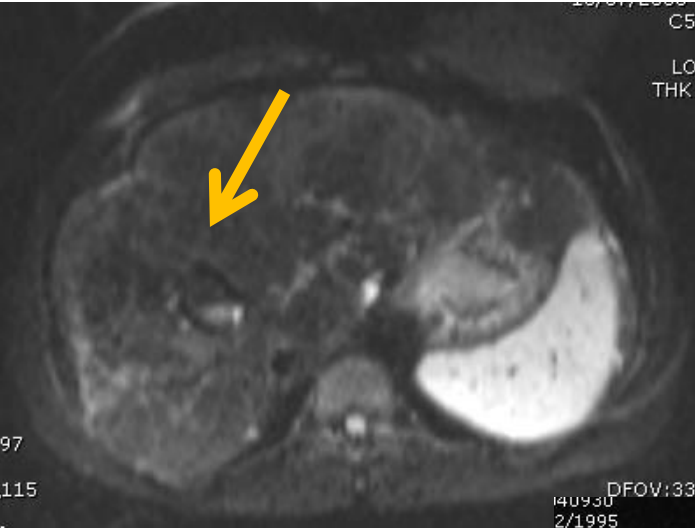
DFOV:33  
IM: 2

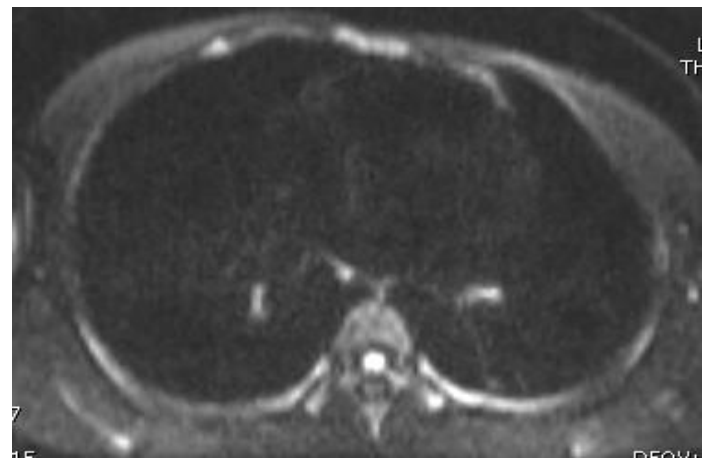
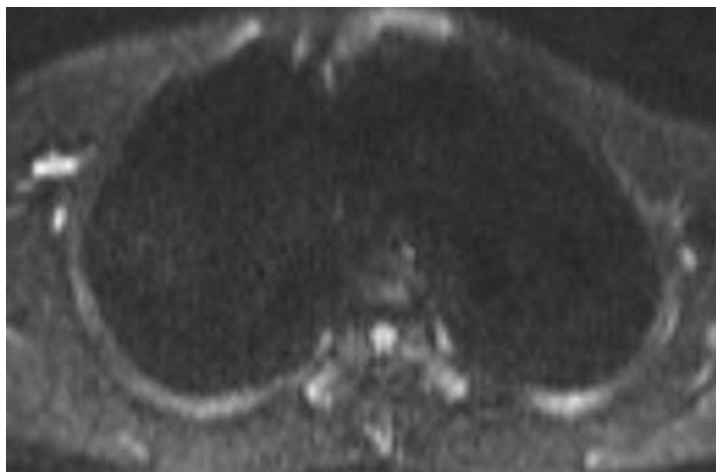
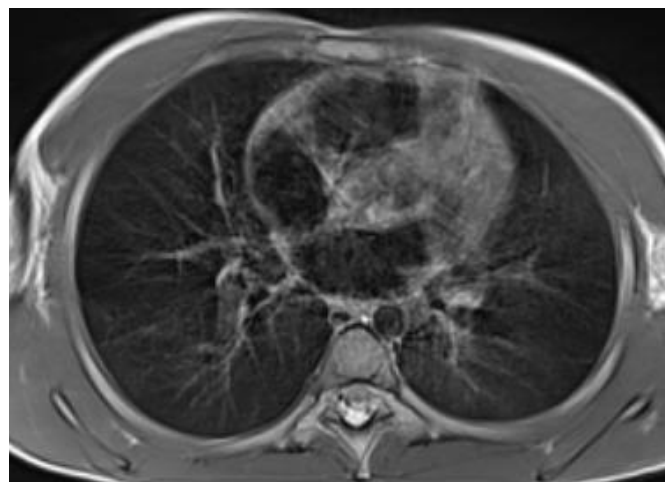
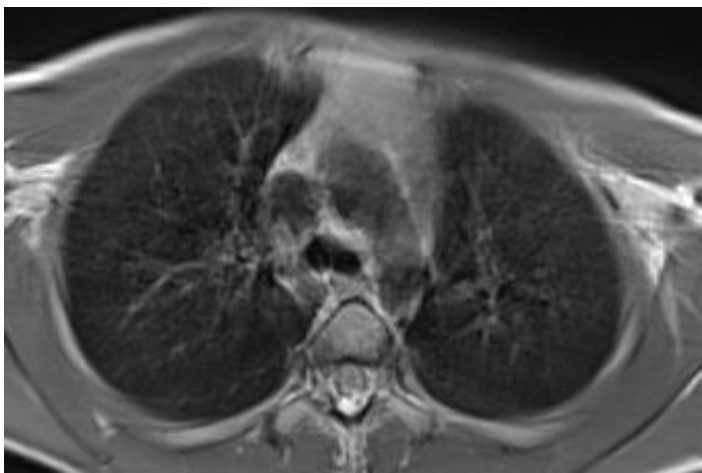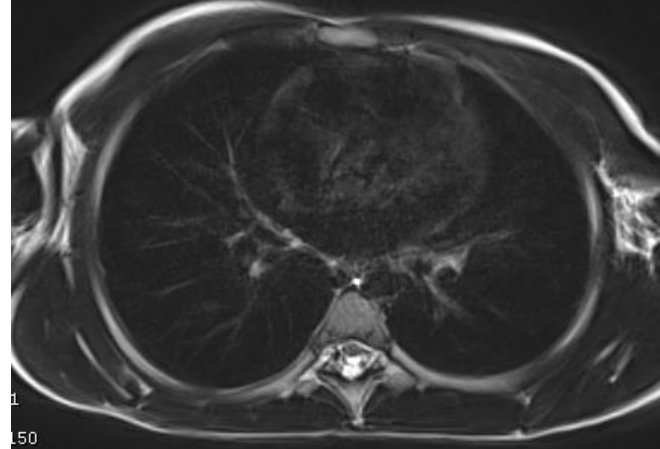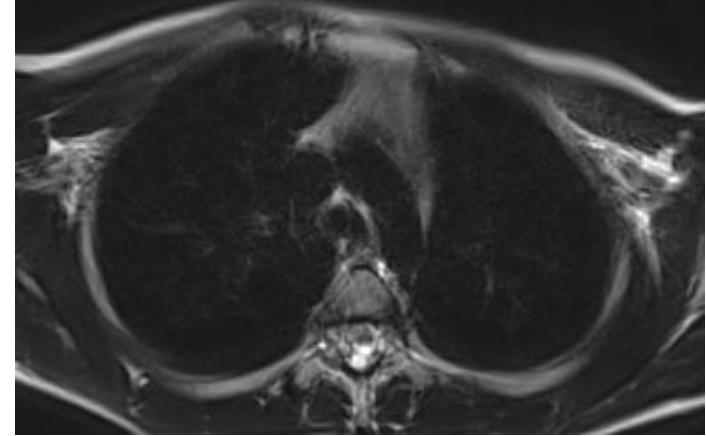
P  
cm

26,03  
1  
92\115

Z:  
C  
W:  
DFOV:33x24

12 aa





# RM: PRO-CONTRO

NO radiazioni

Studio  
morfologico/funzio  
nale

> durata esame

< informazioni?

# TC-RM: $\neq$ di GESTIONE

Programmazione/disponibilità  
macchina

Durata (pz pediatrici)

Condizioni cliniche (tosse)

Tecnico dedicato





RM: RICERCA → PRATICA CLINICA

protocollo adattabile alle esigenze:

- Quali/quante sequenze
- Ausilio di spirometro
- Mezzo di Contrasto
- Controllo post-terapia